

## POSTER PRESENTATIONS

# Royal College of Radiologists Breast Group Annual Scientific Meeting 2011

Glasgow, UK, 7-8 November 2011

Published: 4 November 2011

### Oral presentations

#### O1

##### Automated breast volume scanner: an initial experience

EK Hughes, L Nassar, A Lim, N Barrett, S Comitis, D Cunningham, S Flais, A Gupta, G Ralleigh, V Stewart, W Svensson, R Williamson, N Zaman, K Satchithananda

Charing Cross Hospital, Imperial College Healthcare NHS Trust, London, UK  
*Breast Cancer Research* 2011, **13**(Suppl 1):O1 (doi: 10.1186/bcr2947)

**Introduction** The automated breast volume scanner (ABVS) is the first of its kind and utilises a large, 17 cm × 15 cm high-frequency ultrasound probe which sweeps across the whole breast generating images that can be reformatted into multiple planes and a 3D volume. ABVS will change breast ultrasound practice by: introducing operator standardisation, reproducibility and repeatability of measurement and interpretation; changing who acquires the volume set and how breast ultrasounds are reported; and allowing accurate comparison of previous and current examinations for screening and assessing treatment change.

**Methods** Patients presented to the symptomatic clinic for conventional 2D ultrasound assessment with a variety of conditions. An additional ABVS was performed.

**Results** Cases were classified into: benign – for example, cysts, fibroadenomas, diabetic mastopathy; and malignant.

**Conclusion** We present a review of our initial experience and highlight its advantages over conventional ultrasound, which include: improved mapping of lesions enabling more accurate future assessment and follow-up, and improved assessment of distortion over conventional 2D ultrasound. Further research is required to explore other potential benefits.

#### O2

##### Symptomatic breast services in Ireland: how do they compare with national and international standards?

D O'Leary, L Rainford

UCD, School of Medicine and Medical Science, Dublin, Ireland  
*Breast Cancer Research* 2011, **13**(Suppl 1):O2 (doi: 10.1186/bcr2948)

**Introduction** A study of symptomatic breast units geographically spread over Ireland collected image quality, compression and radiation dose data from 18 mammography units; so how do these optimisation parameters compare nationally and internationally? The mean glandular dose (MGD) diagnostic reference level was proposed for the all-digital breast screening service [1] but not for the symptomatic breast service.

**Methods** The quantitative and qualitative data were analysed using SPSS. Recommendations of MGD diagnostic reference levels were made at various levels for film-screen mammography (FSM) and full-field digital mammography (FFDM) units to match those levels published in worldwide.

**Results** MGDs received by symptomatic breast patients within Ireland are higher than those received in the all-digital Irish Breast Screening service, although the differences for FFDM are not substantial; 55 to 65 mm breast: 1.75 mGy (screening) versus 2.4 mGy (symptomatic) at the 95th percentile. The four-view routine mammography MGDs obtained in symptomatic breast units in Ireland are, however, substantially different from other screening units with mixed FSM/FFDM modalities: 4.5 mGy (UK); 4.98 mGy (USA) versus 5.96 mGy (FFDM, symptomatic) and 9.63 mGy (FSM, symptomatic). Various reasons are proposed for the differences.

**Conclusion** MGD diagnostic reference levels achieved in the screening service may be lower due to the exacting requirements for radiographer training, nonsurgical alteration of patient breasts and equipment quality assurance levels. Greater training of radiographers performing mammography in the symptomatic breast services is required to standardise mammographic projections with regard to MGDs delivered.

##### Reference

1. Baldelli P, McCullagh J, Phelan N, Flanagan F: Comprehensive dose survey of breast screening in Ireland. *Radiat Prot Dosimetry* 2011, **145**:52-60.

#### O3

##### Correlations between shear wave elastography and mammographic findings in invasive breast cancer

MJ Budak, K Thomson, P Whelehan, S Vinnicombe, A Evans  
Dundee Cancer Centre, Ninewells Hospital and Medical School, Dundee, UK  
*Breast Cancer Research* 2011, **13**(Suppl 1):O3 (doi: 10.1186/bcr2949)

**Introduction** Shear wave elastography is a new ultrasound technique which shows promise in the differential diagnosis of solid breast masses. This study compares the mean tumour stiffness with mammographic findings and mammographic density in women with invasive breast cancer.

**Methods** Mammographic morphological features and BIRADS density assessment of the contralateral breast were documented in 96 consecutive patients with operable invasive breast cancer who had undergone shear wave elastography. Mammographic assessment was performed blinded to the elastography and pathological findings. Mean stiffness values of individual tumours were classified as either above or below the average mean stiffness of the cancers. Chi-squared tests for trend were used to compare mean stiffness with mammographic features and density.

**Results** There was no statistically significant difference in the mean stiffness of tumours according to their mammographic features. Mean tumoural stiffness increased with breast density (average mean stiffness 126 kPa, 132 kPa, 154 kPa, and 179 kPa for BIRADS densities 1 to 4, respectively), with a statistically significant trend of stiffness being above average for a cancer in a denser breast. No statistically significant correlation was shown between tumour size or grade (factors known to be associated with increased stiffness) and mammographic density.

**Conclusion** Tissue stiffness of breast cancers is greater in women with mammographically denser breasts. Assuming elastographic stiffness reflects characteristics of stroma and tumour, our findings suggest that tumour-stroma interactions may vary with mammographic density.

#### O4

##### Full-field digital mammography: a retrograde step for small screen-detected cancers?

P Boavida, E O'Flynn, R Wilson, E O'Donovan, S Allen

The Royal Marsden Hospital, London, UK

Breast Cancer Research 2011, 13(Suppl 1):O4 (doi: 10.1186/bcr2950)

**Introduction** Our breast surgery service receives many breast cancer referrals from neighbouring breast screening centres with analogue mammography systems. As hospital protocol we perform repeat full-field digital mammography (FFDM) in these women in an attempt to better stage the primary tumours. The aim of this study is to assess whether FFDM detects more disease than analogue mammography in patients with screen-detected cancer with pathological correlation.

**Methods** Three experienced mammography readers evaluated repeat FFDM in 60 women whilst blinded to the prior analogue studies. Sixty age-matched controls were also assessed. The mammographic findings were then compared with the final surgical pathology. Breast density scores were recorded using Quantra™ software to assess whether this influenced diagnostic accuracy.

**Results** Sixteen (26.7%) analogue mammography-detected cancers were not detected by at least one reader on FFDM. Three (5%) analogue mammography-detected cancers were missed by all three readers on FFDM. Small soft tissue masses represented all of the cancers missed by all three readers. Mean fibroglandular density as assessed by Quantra™ was 15.3 for controls, 13.9 for cancers and 14.2 for cancers not identified by at least one reader. FFDM more accurately staged the DCIS extent than analogue mammography when comparing final surgical pathology, although the result was not significant ( $P = 0.2$ ).

**Conclusion** Not all cancers visualised on analogue mammography can be seen on repeat FFDM performed within 2 weeks, even allowing for biopsy-related bruising. Although DCIS is possibly better staged by FFDM compared with analogue, small soft tissue masses are less well distinguished. This effect does not seem related to background breast density.

#### O5

##### Correlation of ethnicity with breast density as assessed by Quantra™

D Tzias, S George, L Wilkinson, R Mehta, C Lobo, A Hainsworth, A Sharma

St George's Hospital, London, UK

Breast Cancer Research 2011, 13(Suppl 1):O5 (doi: 10.1186/bcr2951)

**Introduction** It is widely accepted that there is an association between mammographic density and breast cancer risk [1]. Various studies have examined relationships between ethnicity and breast density patterns using the Wolfe classification system [2], with a view to investigating potential breast cancer risk. Quantra™ is a volumetric assessment tool, which allows reproducible objective measurement of mammographic breast density, eliminating inter-observer variability. Our study sought to investigate the correlation between ethnicity and breast density using Quantra™ measurements.

**Methods** The Quantra™ value was recorded from the mammograms of symptomatic breast patients at St George's Hospital, London over a 6-month period. We compared three distinct ethnic groups; Black (African and Afro-Caribbean), Asian (Indian subcontinent) and White (Caucasian). Mean Quantra™ values were calculated for each group and the Kruskal-Wallis test was applied.

**Results** A total of 428 patients were included in the study. Mean breast density values for the three ethnic groups were as follows: Black, 24.31%; Asian, 21.94%; White, 24.74%.  $P = 0.0046$  (Kruskal-Wallis).

**Conclusion** There is a statistically significant difference between the objectively measured breast densities of these three ethnic groups. This is of relevance to the assessment of breast cancer risk.

##### References

1. Boyd NF, Guo H, Martin LJ, Sun L, Stone J, Fishell E, Jong RA, Hislop G, Chiarelli A, Minkin S, Yaffe MJ: Mammographic density and the risk and detection of breast cancer. *N Engl J Med* 2007, 356:227-236.
2. Turnbull AE, Kapera L, Cohen ME: Mammographic parenchymal patterns in Asian and Caucasian women attending for screening. *Clin Radiol* 1993, 48:38-40.

#### O6

##### A comparison of the accuracy of digital breast tomosynthesis with supplementary views in the diagnostic workup of mammographic lesions

JC Morel, A Iqbal, C Peacock, DR Evans, RK Wasan, R Rahim, J Goligher,

MJ Michell

King's College Hospital, London, UK

Breast Cancer Research 2011, 13(Suppl 1):O6 (doi: 10.1186/bcr2952)

**Introduction** Supplementary views (SV) are routinely used in the diagnostic workup of mammographic lesions. Previous studies have demonstrated that digital breast tomosynthesis (DBT) increases the accuracy of classification of mammographic lesions [1]. In this study the diagnostic accuracy of SV is compared with DBT.

**Methods** The study included cases from screening assessment and symptomatic clinics requiring further mammographic workup. The cases were read by seven specialist breast radiologists. In the first session, readers read bilateral two-view full-field digital mammography (FFDM) and SV of the lesion. In the second session, at least 1 week later, readers read bilateral two-view FFDM plus one-view DBT in the same projection as the SV. Mammographic scores (1 to 5), lesion type and final outcome were recorded.

**Results** A total of 356 cases were assessed using receiver operative characteristic analysis to evaluate the difference between the two modes. For FFDM plus SV, the area under the curve (AUC) was 0.8807 (95% CI = 0.84374 to 0.91766) and for FFDM plus DBT the AUC was 0.9186 (95% CI = 0.88821 to 0.94895); difference in AUCs was 0.0379 with  $P$  value 0.055.

**Conclusion** These results demonstrate that the accuracy of DBT has borderline superiority to SV in the diagnostic workup of mammographic lesions.

##### Reference

1. Michell MJ, Iqbal A, Wasan RK, Douiri A, Evans DR, Peacock C, Morel JC, Lawinski CP: Phase I trial to determine the performance of digital breast tomosynthesis versus two dimension digital and film-screen mammography [abstract SSQ01-02]. In *96th Scientific Assembly and Annual Meeting; 28 November-3 December 2010; Chicago, IL, USA. RSNA* [http://rsna2010.rsna.org]

#### Poster presentations

#### P1

##### Mammographic image unsharpness: a predictable phenomenon?

A Coltart<sup>1</sup>, C Blythe<sup>2</sup>, M Hair<sup>3</sup>

<sup>1</sup>South West of Scotland Breast Screening Unit, Irvine, UK; <sup>2</sup>Queen Margaret University, Edinburgh, UK; <sup>3</sup>Ayrshire and Arran Health Board, Kilmarnock, UK

Breast Cancer Research 2011, 13(Suppl 1):P1 (doi: 10.1186/bcr2953)

**Introduction** In 2009, the South West of Scotland Breast Screening Unit (SWSBSU) had to repeat 236 examinations due to mammographic image unsharpness. Such recalls were undesirable because of radiation safety issues, anxiety caused and cost. The aim of this study was to model predictors of recall that could be used in clinical practise to help reduce the numbers of repeat examinations required due to blurring.

**Methods** This retrospective study compared two sample groups ( $n = 118$ ), randomly selected from a cohort of women who attended the SWSBSU in 2009 ( $n = 16,194$ ). Tests of significance were used to compare a range of variables in each group and logistic regression was employed to produce four predictor models for recall. Statistical analysis was carried out by the authors using SPSS version 18.

**Results** A 12 mm increase in compressed breast thickness (CBT), a 50 mAs increase in exposure or a 350 ms increase in exposure time will double the odds of recall due to unsharpness. Also, an increase of 2 kVp, when imaging a breast with a CBT of 60 mm, will reduce the odds of recall by approximately 39%.

**Conclusion** CBT is a major determinant of recall due to unsharpness. Within the context of the reported increase in average CBT [1] and rising national obesity, reconsideration of kVp selection criteria may be necessary to minimise the incidence of recall due to unsharpness.

## Reference

1. Robinson M, Kotre C: Trends in compressed breast thickness and radiation dose in breast screening mammography. *Br J Radiol* 2008, **81**:214-218.

## P2

### Outcomes following B3/B4 needle core biopsy in South East London Breast Screening Service 2000 to 2010

K Lynes<sup>1</sup>, I Nikolopoulos<sup>1</sup>, N Akbar<sup>2,3</sup>, M Michell<sup>2,3</sup>, K Thakur<sup>1,3</sup>  
<sup>1</sup>Queen Elizabeth Hospital, South London Healthcare NHS Trust, London, UK; <sup>2</sup>King's College Hospital NHS Foundation Trust, London, UK; <sup>3</sup>South East London Cancer Network, London, UK  
*Breast Cancer Research* 2011, **13**(Suppl 1):P2 (doi: 10.1186/bcr2954)

**Introduction** Needle core biopsy (NCB) is frequently used in assessing screen-detected breast lesions. Uncertainty remains over appropriate management of NCBs reported as 'uncertain malignant potential' (B3) or 'suspicious of malignancy' (B4). This study aims to analyse a large screening dataset to establish positive predictive values (PPVs) for malignancy on excision biopsy, for different classifications of B3 and for B4 NCBs.

**Methods** Retrospective analysis was conducted of prospectively collected data for South East London Breast Screening Service. A total of 5,324 patients underwent NCB between 2000 and 2010, including 14G (ultrasound-guided) and 10G vacuum-assisted biopsies (stereo-guided). A total of 444 were B3 (8.3%) and 38 (0.7%) were B4. NCBs reported as B3 were classified by pathological subtype and PPVs for malignancy calculated for each subtype. Outcomes following B4 NCB were also assessed.

**Results** The overall PPV for malignancy for B3 NCBs was 25% and for B4 NCBs was 74%. The PPVs for each subtype of B3 classification were as follows: papillary 14%, atypical intraductal epithelial proliferation 35%, phyllodes 11%, lobular 47%, complex sclerosing lesion/radial scar 6%, columnar cell 29%.

**Conclusion** Our findings indicate that NCBs reported as B4 should be excised as they have a high likelihood of malignancy on excision biopsy. The PPVs for subtypes of B3 NCBs vary considerably. However, B3 subtypes with atypia should be treated with a higher level of suspicion and preferably be surgically excised. Decisions regarding further assessment should be made in a multidisciplinary setting.

## P3

### Objective critical appraisal of mammography images in clinical audit: can we achieve this?

D O'Leary<sup>1</sup>, A Teape<sup>2</sup>, J Hammond<sup>2</sup>, L Rainford<sup>1</sup>  
<sup>1</sup>UCD, School of Medicine and Medical Science, Dublin, Ireland; <sup>2</sup>BreastCheck Irish National Breast Screening, Dublin, Ireland  
*Breast Cancer Research* 2011, **13**(Suppl 1):P3 (doi: 10.1186/bcr2955)

**Introduction** Objective critique of mammographic image quality (IQ) is vital to assess efficacy of services provided by mammography units. The European Guidelines for Screening Mammography require an inadequate image rate of 3%. The subjectivity within current IQ criteria allows symptomatic mammograms with surgically altered breasts to appear to achieve these requirements; however, as evidenced in the analysis of symptomatic breast images within a national optimisation study, current methods of classification for symptomatic mammograms are largely subjective, resulting in poor inter/intra-departmental agreement on IQ.

**Methods** The European Quality Criteria for mammographic IQ and the Breast Screening quality criteria classification of images as inadequate/moderate/good/perfect were modified to remove all subjective criteria. These objective classifications of IQ were tested for inter/intra-rater reliability by a panel of experts and compared with original IQ criteria. Further objective measures such as breast volume, density and pectoral-nipple measurements were carried out.

**Results** When tested with 278 surgically modified breast images from the larger research sample, inter-rater reliability ( $K > 0.701$ ;  $P < 0.001$ ) and agreement (Pearson's correlation  $r > 0.884$ ;  $P < 0.01$ ) by the evaluation panel were higher than when the original quality criteria methods were used. The intra-rater reliability was equally high ( $K > 0.7$ ;  $P < 0.001$ ) with agreement via Pearson's correlation at  $r > 0.844$ ;  $P < 0.01$ .

**Conclusion** A method of scoring images combining the most objective components of major European, national and international image scoring systems is suggested. The removal of subjectivity from the scoring systems will remove all doubt regarding the achievement of high image-quality goals for all mammography departments.

## P4

### Comparison of analogue and digital mammographic appearances of screen-detected invasive breast cancers

TW Jones, G Bansal, H Farmer, B Orr, H Russell, L Hobson, D Godden, I Lyburn  
Gloucestershire Breast Screening Service, Cheltenham, UK  
*Breast Cancer Research* 2011, **13**(Suppl 1):P4 (doi: 10.1186/bcr2956)

**Introduction** Our UK Breast Screening Service changed overnight wholesale from analogue to digital mammography on 5 October 2009. This has meant that we have two unmixed cohorts to directly compare. We wish to evaluate whether any digital mammography has changed our cancer detection, and whether any features of these cancers have altered.

**Methods** A NBSS database search for all screen detected cancers in the periods 1 year prior to the digital changeover; and 1 year after. This period was sufficiently historical to expect all cancer diagnosis episodes to have closed by the time of study. The screening packets for all these patients were pulled, and films and pathology analysed by the researchers. The information was directly entered into an anonymised spreadsheet.

**Results** For 2008 to 2009 analogue: 24,876 women invited, 20,557 screened, 944 recalled for assessment, 155 diagnosed with cancer; mean age 59.7. For 2009 to 2010 digital: 32,143 women invited, 25,088 screened, 1,230 recalled for assessment, 221 diagnosed with cancer; mean age 61.0.

**Conclusion** Screening uptake figures were high in this unit (78% and 82% for each group). Cancer detection rates were significantly increased in the age 50 to 64 group (analogue 4.6 and digital 6.2/1,000 women screened). Mean cancer sizes were smaller on digital mammography but this also corresponded with smaller mean pathological sizes. Adjusting for this, the digital system still identified smaller cancers than the analogue system. Overall, cancer detection seems improved by our change to digital mammography.

## P5

### Apparent diffusion coefficient of normal breast tissue during the menstrual cycle at 3 Tesla

N AlRashidi, T Ahearn, B Jagpal, T Redpath, F Gilbert  
University of Aberdeen, UK  
*Breast Cancer Research* 2011, **13**(Suppl 1):P5 (doi: 10.1186/bcr2957)

**Introduction** Diffusion-weighted magnetic resonance imaging (DW-MRI) is a quantitative MRI technique that provides physiological information by measuring the degree of water molecule diffusion within the extracellular space. It gives a quantitative measurement known as the apparent diffusion coefficient (ADC) value. The aim of the study is to show the influence of the menstrual cycle on breast ADC values and the relationship of the ADC to transverse relaxation (T2) value.

**Methods** Female volunteers had one MRI scan per week over 4 weeks using a 3 T MRI scanner. The ADC of the fibroglandular tissue was measured using a single-shot SE-EPI with four  $b$  values (0, 50, 150, and 800 s/mm<sup>2</sup>). The T2 relaxation time was measured using T2w turbo spin echo (TSE) with four echo times (20, 40, 60, and 80 ms). ADC and T2 maps were generated automatically by standard Philips software.

**Results** The study was performed on 11 healthy volunteers (23 to 41 years old) with a regular menstrual cycle. There is no significant difference between ADC and T2 values for the 4 weeks. Pearson's correlation coefficient indicated a negative correlation between ADC and T2 values. See Table 1.

**Conclusion** The study shows that ADC values are not affected by the normal hormonal fluctuations during the menstrual cycle.

Table 1 (abstract P5)

Parameter	Week 1	Week 2	Week 3	Week 4
ADC ( $\times 10^{-3}$ mm <sup>2</sup> /s)				
Fibroglandular tissue	1.7 $\pm$ 0.2	1.7 $\pm$ 0.3	1.7 $\pm$ 0.3	1.7 $\pm$ 0.3
T2 (ms)				
Fibroglandular tissue	57.6 $\pm$ 7	58 $\pm$ 7	58.7 $\pm$ 8	60 $\pm$ 10
Adipose tissue	78 $\pm$ 4	77 $\pm$ 4	77 $\pm$ 4	77 $\pm$ 4

Data presented as mean  $\pm$  SD.

## P6

### Quantification of breast cancer risk based on the UK five-point classification system

D Tzias, S George, L Wilkinson, R Mehta

St George's Hospital, London, UK

Breast Cancer Research 2011, 13(Suppl 1):P6 (doi: 10.1186/bcr2958)

**Introduction** The UK five-point classification for radiological assessment of mammograms and ultrasound scans broadly enables evaluation of cancer risk [1], but no specific probabilities are incorporated into this system. By comparison, the widely accepted BI-RADS scoring system does include percentage cancer risk for each category [2]. Our study sought to investigate the cancer probability for each of the five radiological grades in the UK scoring system amongst a large group of mammograms.

**Methods** The reports of 3,149 mammograms performed over a 10-month period within the symptomatic breast service at St George's Hospital, London were analysed. The corresponding histopathology reports were collected for identification of malignant cases. Percentage cancer risk was calculated for each category within the UK five-point classification system.

**Results** The pathology reports corresponding to each of the 3,149 mammograms revealed 78 cases of malignancy. Data analysis gave the following cancer probabilities for each category: M1, 0.3%; M2, 0.6%; M3, 13.5%; M4, 63.6%; and M5, 83.0%.

**Conclusion** We propose that calculation of cancer risk for each category within the UK five-point scoring system is a valuable parameter. It enables accurate performance monitoring within a breast unit as well as comparison with national/international standards.

#### References

1. Maxwell AJ, Ridley NT, Rubin G, Wallis MG, Gilbert FJ, Michell MJ: Royal College of Radiologists Breast Group: The Royal College of Radiologists Breast Group breast imaging classification. *Clin Radiol* 2009, **64**:624-627.
2. Orel SG, Kay N, Reynolds C, Sullivan DC: BI-RADS categorization as a predictor of malignancy. *Radiology* 1999, **211**:845-850.

## P7

Abstract withdrawn by author.

## P8

### Ultrasound staging and fine needle aspiration cytology: how well do they predict breast cancer nodal involvement?

JM Schneider<sup>1</sup>, A Leaver<sup>2</sup>

<sup>1</sup>University of Dundee, UK; <sup>2</sup>Gateshead Health NHS Foundation Trust,

Gateshead, UK

Breast Cancer Research 2011, 13(Suppl 1):P8 (doi: 10.1186/bcr2960)

**Introduction** Ultrasound and fine needle aspiration cytology (FNAC) are used to provide presurgical axillary assessment in breast cancer, in line with NICE guidance. An N1 to N5 ultrasound staging process has been recently introduced. The significance of the new N staging system and overall preoperative staging results has been analysed.

**Methods** Patient data were collected during MDTs and from the electronic results and analysed retrospectively. Patients with ultrasound score N and/or axillary FNAC were included if they had subsequent histology (sentinel lymph node biopsy or axillary clearance).

**Results** A total of 125 patients had histological node samples following ultrasound assessment and/or FNAC. Fifty-eight had both ultrasound and FNAC. Ultrasound/FNAC were found to be 82% (27/33)/79% (23/29) sensitive and 100% (44/44)/100% (41/41) specific, respectively. The overall preoperative staging process sensitivity was 65%. The positive predictive values of N3, N4, and N5 were 31% (10/32), 50% (6/12) and 100% (11/11), respectively.

**Conclusion** Combining ultrasound and FNAC assessment provides a valuable method of preoperative lymph node staging, guiding surgical management, reducing unnecessary surgery and the number of repeat operations. Our ultrasound N staging system correlates well with final histology, and we now plan to introduce repeat axillary biopsy with high stage N/negative FNAC patients, to attempt an overall increase in preoperative staging sensitivity/a more effective management pathway.

## P9

### Incidence and outcome of 18-fluorodeoxyglucose positron emission tomography/computed tomography-detected breast lesions

LS Haine, G Rutherford, CE Ingram, IJ Jolley, O Hatsiopoulou

The Royal Hallamshire Hospital, Sheffield, UK

Breast Cancer Research 2011, 13(Suppl 1):P9 (doi: 10.1186/bcr2961)

**Introduction** Breast cancer accounts for around 16% of female deaths in the UK. Usual diagnosis is via the symptomatic pathway or screening. Positron emission tomography/computed tomography (PET/CT) is a modality with increasing applications in staging malignancies and investigating symptoms. It increasingly detects incidental breast lesions. The aim of this study was to evaluate the incidence and outcome of PET/CT-detected breast abnormalities.

**Methods** The radiology information server (CRIS) was interrogated to produce a list of PET/CT scan results containing the word 'breast' over 4 years. Scans performed on patients with known breast malignancy were excluded. A further CRIS search was used to determine if subsequent breast imaging was performed. Pathology was obtained and hospital notes were reviewed.

**Results** Thirty patients were found to have incidental breast lesions on PET/CT scanning. There were 19 masses, seven areas of focal fluorodeoxyglucose (FDG) uptake, two areas of calcification, one case of asymmetry and one area of thickening. In total, 16/30 patients underwent breast assessment (11 masses, four focal increased uptake and one bilateral calcification). Out of 11 patients with masses, six were proven to have corresponding invasive cancers and two had ductal carcinoma *in situ*. The remaining three were normal or had benign disease. Of the four patients with focal increased FDG uptake, one patient had invasive cancer, one had a fibroadenoma and two were normal. The bilateral calcifications corresponded to lymph nodes.

**Conclusion** The incidental detection of breast malignancy by PET/CT was significant at 56%. Breast assessment should be performed in this population.

## P10

### Image quality and compression force: the forgotten link in optimisation of digital mammography?

D O'Leary, T Grant, L Rainford

UCD, School of Medicine and Medical Science, Dublin, Ireland

Breast Cancer Research 2011, 13(Suppl 1):P10 (doi: 10.1186/bcr2962)

**Introduction** Numerous publications suggest the compression force applied in mammography must be reduced to encourage initial/continued attendance by women. These studies (many with limited patient populations) have not used sufficient statistical correlation of compression force data to image quality to reinforce these contentions. The growth of digital mammography has enabled a comparison of compression force and image quality in analogue and digital images.

**Methods** A quantitative and qualitative study of mammography units within Ireland collected comprehensive image quality, compression (force and depth) and radiation dose data from 4,790 patient images. The data were analysed using univariate analysis of variance and SPSS statistics including ANOVA to re-examine the connections between all parameters for optimisation of mammographic imaging.

**Results** The amount of compression force consistently showed significant effects on the image quality; perfect and good images consistently required significantly more compression force than moderate and inadequate images. This was especially apparent in digital images. The mean compression force (Newtons) required to produce a perfect image was: 121.34 N for digital craniocaudal; 134.23 N for digital mediolateral oblique; 112.23 N for analogue craniocaudal; and 129.66 N for analogue mediolateral oblique. Only 2% of patients expressed dissatisfaction with the higher compression forces that were applied.

**Conclusion** Compression forces are too low, affecting image quality; greater compression force by 11 to 15 N is needed to achieve a perfect image especially in full-field digital mammography. Greater training of radiographers performing mammography is required to standardise the undertaking of the mammographic projections with regard to achievable compression depth and the application of compression force delivered to the breasts of Irish women attending the symptomatic breast services.

### P11

#### Large-bore vacuum-assisted biopsy of axillary lymphadenopathy

ND Forester<sup>1</sup>, P Burrows<sup>1</sup>, A Jack<sup>2</sup>, A-M Wason<sup>1</sup>

<sup>1</sup>Pennine Breast Unit, St Luke's Hospital, Bradford, UK; <sup>2</sup>Haematological Malignancy Diagnostic Services, Leeds, UK

Breast Cancer Research 2011, 13(Suppl 1):P11 (doi: 10.1186/bcr2963)

**Introduction** Lymphoma diagnosis conventionally requires nodal excision biopsy, to allow histological subclassification of tumours on samples with preserved tissue architecture. As such, diagnostic accuracy following 16G or 18G core biopsy is difficult. Large-bore vacuum-assisted biopsies, such as Mammotome, can percutaneously sample large volumes of breast tissue with excellent tissue architecture preservation. We describe vacuum-assisted biopsy of axillary nodes to investigate lymphadenopathy in surgically high-risk patients.

**Methods** Eight patients (seven male, one female; median age 52, range 27 to 65) underwent ultrasound-guided, 8G vacuum-assisted biopsy of axillary lymphadenopathy between March 2009 and February 2011. The median largest node size was 28 mm (range 14 to 87 mm). Three patients had previous ultrasound-guided 18G core biopsies, which were insufficient for diagnosis. Between three and 15 cores were obtained (median = 7) and sent fresh to the Haematological Malignancy Diagnostic Services.

**Results** In seven patients, 8G vacuum-assisted biopsy provided sufficient histologically intact nodal material to be fully diagnostic. In one patient, tissue was suspicious for lymphoma, but insufficient for final diagnosis. In seven patients with adequate tissue sampling, six had lymphoma and one had reactive lymphadenopathy. Of the lymphoma diagnoses, four were new diagnoses (two Hodgkin, one follicular, one diffuse large B-cell lymphoma) and two were recurrent lymphomas. No procedure-related complications occurred.

**Conclusion** Ultrasound-guided large-bore vacuum-assisted biopsy can safely biopsy axillary lymphadenopathy. Furthermore, samples obtained have sufficiently preserved tissue architecture to allow a conclusive diagnosis of lymphoma, without requiring surgical intact node excision. In our institution, this technique has proved useful in high-risk surgical candidates, and where nodal size would have made surgery technically difficult.

### P12

#### Arbitration cancers: analysis from two screening rounds for the Coventry, Solihull and Warwickshire screening service

S Garnett

University Hospital, Coventry, UK

Breast Cancer Research 2011, 13(Suppl 1):P12 (doi: 10.1186/bcr2964)

**Introduction** Third-reader screen-reading is undertaken in our unit to reconcile discordant reader results. An audit has been conducted to analyse the nature of cancers diagnosed at assessment for arbitration recalls. The objective was to identify and describe discordant cancer types and appearances.

**Methods** The study period covered two screening rounds. Arbitration records were reviewed and mammographic shape, size, position, cancer type and grade, and histological size were recorded. Both film and digital cases were included and compared. Descriptive statistics were produced comparing discordant and concordant cancers.

**Results** A total of 128 arbitration cancers were analysed (3.6% of total cancers,  $n = 3,516$ ). There were 5,635 total arbitrations of which 27% ( $n = 1,519$ ) were assessed. A total of 8.4% were cancer. There were a higher number of smaller sized (1 to 15 mm) cancers in the arbitrated group, 61% compared with 48% in the concordant group. There was no difference between film and digital cancer size. More cancers appeared as lobular, tubular and DCIS in the arbitration group. There was an equal spread of calcification and mass type mammographic appearances.

**Conclusion** No previous study had specifically analysed arbitration (third-reader) cancers. This audit showed that lesion size is smaller, all cancer types are present and both calcifications and masses are equally represented. Digital cases did not show any smaller cancers for the discordant group. A future audit will be to look at the arbitration interval cancers; that is, when two readers have not recalled a subsequent false positive case, to assess the features that have been ignored.

### P13

#### Early identification of substandard breast screening performers

L Dong, Y Chen, AG Gale

Loughborough University, Loughborough, UK

Breast Cancer Research 2011, 13(Suppl 1):P13 (doi: 10.1186/bcr2965)

**Introduction** All UK breast screeners can voluntarily undertake the PERFORMS scheme, where they examine recent screening cases receiving immediate feedback. Once all individuals have participated, data are calculated on how they performed compared with peers allowing poor performers to be identified. A way of potentially identifying such poor performers much earlier is proposed.

**Methods** Information from the last round of the PERFORMS scheme was reanalysed for which the low performance threshold value was known. Data for randomly selected small groups of participants were repeatedly bootstrapped with the aim of artificially determining a threshold of low performance and comparing this with the known actual threshold. Using a varying number from four to 50 participants, a sample of 1,000 randomly selected small groups was constructed for each number of participants. After bootstrapping each small group, a distribution of 1,000 thresholds of low performance was constructed and median values and standard errors of this distribution calculated to determine how the number of participants affected the estimation accuracy.

**Results** The standard error of the estimated threshold reduced as group size increased, indicating better estimation accuracy. Using data from as few as 10 people the artificial threshold approached the known actual threshold of poor performance.

**Conclusion** Individuals who are performing less than their peers on the scheme can be identified early without all screeners having first taken part. Whilst not an absolute outlier measure, this information can be fed back in a timely manner, so enabling the individual to improve their cancer identification performance.

### P14

#### Comparison of mammographic findings and need for ultrasound and biopsy in women undergoing wide local excision and either intraoperative radiotherapy or external beam whole breast irradiation

A Romsauerova, J Dewar, D Brown, A Evans

Dundee Cancer Centre, University of Dundee, UK

Breast Cancer Research 2011, 13(Suppl 1):P14 (doi: 10.1186/bcr2966)

**Introduction** TARGIT-A is a recent prospective randomised multicentre controlled trial comparing intraoperative radiotherapy (IORT) and external beam whole breast irradiation (EB). The aim of this study was to compare localised and generalised findings at follow-up mammography and the need for interventions such as ultrasound and biopsy between women in the two treatment arms from a single recruiting centre.

**Methods** We have compared the 61 women who received IORT alone with the 63 women who received EB alone. All mammograms were reviewed by radiologists blinded to the treatment received. The focal soft tissue appearance was classified. The presence of generalised skin thickening and increased density was recorded. The performance of ultrasound and/or biopsy was recorded.

**Results** The number of follow-up mammograms and length of follow-up was similar in both groups (2.46 IORT vs. 2.09 EB and 3.27 years IORT vs. 3.0 years EB). There was no difference in the mammographic appearance of the postoperative site between the two groups. However, generalised skin thickening and increase in density were more common in the EB group compared with the IORT group (20 of 63 (37%) vs. 10 of 61 (16%),  $P = 0.04$  and 20 of 63 (37%) vs. 5 of 61 (8%),  $P = 0.001$ , respectively). Ultrasound at follow-up was more frequent in the IORT group compared with the EB group (15 of 61 (25%) vs. 7 of 63 (11%),  $P = 0.049$ ).

**Conclusion** Generalised reactions on mammography are more common following EB compared IORT. However, follow-up ultrasounds were more frequent in the IORT group.

#### P15

##### Vacuum-assisted core biopsy of the breast

S Saikia, L Lunt

Queen Elizabeth Hospital, Gateshead, UK

Breast Cancer Research 2011, 13(Suppl 1):P15 (doi: 10.1186/bcr2967)

**Introduction** Vacuum-assisted core biopsy (VACB) is a highly effective method of sampling breast tissue. Breast care nurses, at the Queen Elizabeth Breast Unit in Gateshead, raised concerns about pain experienced by patients during this procedure. The aim of this study was to assess how patients perceive VACB.

**Methods** Prospective data collection for 6 months from November 2010 of consecutive patients undergoing VACB. Data were collected using a questionnaire about pain experienced immediately and 4 weeks post procedure, using the Numerical Rating Scale and Short Form McGill validated pain scores [1].

**Results** Fifty questionnaires were completed. Immediately post procedure, 88% felt no or mild pain. Of those reporting pain, 100% had a sensory dimension. Four weeks later the memory of the pain experienced during the procedure was worse in 46%. In this group, pain 4 weeks post procedure had an affective dimension in 50% of cases. Four weeks post procedure, 91% felt no or mild pain. One hundred per cent would reassure a friend about the procedure.

**Conclusion** Minimal pain was experienced immediately or 4 weeks post procedure. There is a discrepancy between pain experienced during the procedure compared with the memory of it. The effect of the biopsy result could be a contributory factor. Further work linking responses to histology may be revealing.

##### Reference

1. Melzack R: The McGill Pain Questionnaire: major properties and scoring methods. *Pain* 1975, 1:277-299.

#### P16

##### Preoperative estimation of the prognosis of invasive breast cancer, based on ultrasound size, core biopsy grade and percutaneous axillary lymph node biopsy

O Elseedawy, C Purdie, L Jordan, S Vinnicombe, P Whelehan, A Thompson, A Evans

Ninewells Medical School, Dundee, UK

Breast Cancer Research 2011, 13(Suppl 1):P16 (doi: 10.1186/bcr2968)

**Introduction** Assessment of the prognosis of invasive breast cancer prior to surgical resection may influence patient management. The aim of this study was to calculate the Nottingham Prognostic Index (NPI) from preoperative information and compare this with the NPI generated by the surgical pathology findings.

**Methods** The preoperative Nottingham Prognostic Index (PNPI) was calculated in 46 consecutive women undergoing primary surgery for invasive breast cancer. The parameters used were imaging size (normally by ultrasound), tumour grade on core biopsy, and axillary

lymph node assessment including core biopsy where appropriate. Values were divided into good (<3.41), moderate 1 (3.41 to 4.4), moderate 2 (4.41 to 5.4) and poor (>5.4) prognostic groups. Intraclass correlation coefficients (ICC) were calculated to compare the PNPI with the postoperative NPI.

**Results** Comparison of the PNPI and NPI gave an ICC of 0.68 (95% CI = 0.48 to 0.81), indicating fair to good agreement. In 39 of 46 women (85%), the PNPI was within one point of the NPI and in 34 (74%) it was within 0.5. Thirty women (65%) were assigned to the correct NPI group by the PNPI. Twelve (26%) were assigned to the adjacent NPI group. In 14 women the NPI group was worse than the PNPI, and in two it was better because the tumours were downgraded at postoperative pathology.

**Conclusion** Preoperative estimation of the NPI approximates to the definitive NPI in the majority of women studied, and could therefore be used to guide systemic treatment decisions preoperatively.

#### P17

Abstract withdrawn by author.

#### P18

##### An audit of breast imaging scoring by radiologists, in cases of proven malignancy

JR Powell, B Mucci

Greater Glasgow NHS Trust, Glasgow, UK

Breast Cancer Research 2011, 13(Suppl 1):P18 (doi: 10.1186/bcr2970)

**Introduction** In 2009 the Royal College of Radiologists Breast Group set out a classification system for breast imaging scoring [1]. A score of 4 'suspicious of malignancy' or 5 'highly suspicious of malignancy' should be used 'in most cases' of proven breast cancer. However, there is no universally accepted target for this in the UK. The American BIRADS system suggests a 98% target [2]; however, their scoring system is slightly different.

**Methods** We examined imaging reports (mammography, ultrasound and MRI) of patients diagnosed with a breast malignancy attending the symptomatic breast clinic in 2009. Our aim was to determine an achievable target for correctly scoring breast imaging.

**Results** A total of 203 patients' imaging was examined. One hundred per cent of reports included a score. Ninety per cent of the cancers were scored 4 or 5. In three underscored cases, radiologist opinion was clouded by the fact the patient had had preceding FNA. Cases of cancer recurrence also proved difficult to correctly score.

**Conclusion** We suggest a target of 90 to 95% of all breast cancers being scored 4 or 5. A 95% target is achievable especially if FNA/biopsy is left until after imaging has been performed.

##### References

1. Maxwell A, et al: The Royal College of Radiologists Breast Group breast imaging classification. *Clin Radiol* 2009, 64:624-627.
2. Liberman L, et al: The Breast Imaging Reporting and Data System. *Am J Roentgenol* 1998, 171:35-40.

#### P19

##### Every second counts: digital and analogue mammography – comparison of reading times at the Queen Elizabeth Breast Screening Unit, Gateshead, UK

GD Bristow, AJ Potterton, LG Lunt

The Queen Elizabeth Hospital Breast Screening Unit, Gateshead, UK

Breast Cancer Research 2011, 13(Suppl 1):P19 (doi: 10.1186/bcr2971)

**Introduction** In the NHS Breast Screening Programme (NHSBSP) there is a transition to digital mammography following recommendations made by the Cancer Reform Strategy [1]. A number of US studies have demonstrated that the time taken to interpret digital mammography is longer than that for analogue [2,3]. There are no published data about this from the NHSBSP.

**Methods** Over a 2-month period, 11 readers were timed in their interpretation of batched analogue or digital mammograms. These were either hung on a multiviewer or preloaded onto Sectra PACS.

Previous images were not digitised. A total of 396 batches were included in the analysis (unpaired *t* test), 330 digital and 66 analogue.

**Results** It takes more time to report a digital mammogram compared with analogue ( $40 \pm 1$  vs.  $35 \pm 2$  seconds,  $P < 0.05$ ). There is no difference in the time taken to report prevalent screens between the analogue and digital groups ( $34 \pm 7$  vs.  $39 \pm 2$  seconds). The incident screens were quicker to interpret as analogue.

**Conclusion** Our data support the hypothesis that digital interpretation is slower than analogue (albeit by 5 seconds) but in the absence of needing to compare with previous images there is no difference between the two modalities.

#### References

1. *Cancer Reform Strategy*. Department of Health; December 2007.
2. Berns EA, Edward Hendrik R, Solari M, et al.: Digital and screen-film mammography: comparison of image acquisition and interpretation times. *Am J Roentgenol* 2006, 187:38-41.
3. Haygood TM, et al.: Timed efficiency of interpretation of digital and film-screen screening mammograms. *Am J Roentgenol* 2009, 192:216-220.

#### P20

##### Risk factors for lymph node metastasis in patients with unifocal breast cancer

A Robinson<sup>1</sup>, M O'Keeffe<sup>1,2</sup>, A Leaver<sup>1</sup>

<sup>1</sup>Gateshead Health NHS Foundation Trust, Gateshead, UK; <sup>2</sup>Newcastle University, Newcastle, UK

*Breast Cancer Research* 2011, 13(Suppl 1):P20 (doi: 10.1186/bcr2972)

**Introduction** In our Trust, in line with NICE guidance, all breast cancers undergo preoperative axillary ultrasound and, where indicated, needle testing. The current overall sensitivity of this process in our Trust is 57%. This study investigates tumour size, type and location as possible factors for patient triage to repeat preoperative axillary staging, aiming to increase our preoperative axillary staging sensitivity.

**Methods** This prospective study included all patients diagnosed and operated on for unifocal breast cancer in our Trust from September to December 2010. Descriptive statistics, chi-squared and logistic regression were performed upon data collated at MDT meetings.

**Results** Logistic regression of 101 females implies that as tumour size increases by 1 cm, nodal disease risk is 1.75 times larger, with 95% confidence limits. Comparing tumours  $< 20$  mm with those  $> 20$  mm, nodal disease risk is 5.818 times larger in the  $> 20$  mm group ( $P < 0.0005$ ). No significant difference was found in nodal disease risk between the histological tumour types, although numbers of lobular and tubular carcinomas were small ( $P = 0.633$ ). Data suggested a difference (0.27 $\times$  smaller risk in UIQ versus UOQ) in probability of axillary node metastasis with tumour location with 95% confidence limits.

**Conclusion** This study demonstrates a clear and statistically significant association between tumour size and nodal disease. The data also suggest a difference in probability of nodal disease with different tumour location, although increased patient numbers are needed to confirm this. A larger trial for stratifying patients for single or double preoperative staging of the axilla is recommended.

#### P21

##### Can radiation dose in mammography be further reduced by improving the image quality?

D O'Leary, L Rainford

University College Dublin, Ireland

*Breast Cancer Research* 2011, 13(Suppl 1):P21 (doi: 10.1186/bcr2973)

**Introduction** Efforts to reduce radiation dose should be *linked to and limited by* image quality and the radiation dose should only be lowered to levels *compatible with* image quality for adequate diagnosis; this is optimisation of mammography. Despite this link between image quality and mean glandular dose (MGD), the MGD is proposed only with regard to compression level achieved or population percentile, not image quality required/achieved.

**Methods** A study of symptomatic breast units geographically spread over Ireland collected image quality and radiation dose data. The quantitative and qualitative data were analysed using mathematical

modelling and SPSS statistics including ANOVA. High image quality was matched to lowest achievable radiation doses; inadequate images were discarded from the dataset for recommendations of achievable MGD.

**Results** MGDs received by perfect images are significantly lower than the radiation doses received by inadequate images. This is seen in both digital images and film-screen images and for both mammographic projections: digital craniocaudal,  $F(3,978) = 2.841$ ,  $P = 0.37$ ; digital mediolateral oblique,  $F(3,977) = 4.896$ ,  $P = 0.002$ ; analogue craniocaudal,  $F(3,785) = 7.993$ ,  $P < 0.001$ ; analogue mediolateral oblique,  $F(3,783) = 7.961$ ,  $P < 0.001$ . The mean MGD in mGy required to produce a perfect image in each of the categories: digital craniocaudal, 1.23 mGy; digital mediolateral oblique, 1.28 mGy; analogue craniocaudal, 2.10 mGy; analogue mediolateral oblique, 2.25 mGy.

**Conclusion** The publication of average glandular dose must be linked to image quality achieved and the percentage of inadequate images in the data collection must be explicit. The radiation doses can be lowered further in digital imaging by greater training of radiographers to consistently achieve perfect mammography images.

#### P22

##### Audit of accuracy of ultrasound-guided axillary core biopsy

A Anand, R Henderson

Darlington Memorial Hospital, Darlington, UK

*Breast Cancer Research* 2011, 13(Suppl 1):P22 (doi: 10.1186/bcr2974)

**Introduction** Sentinel lymph node biopsy (SLNB) is the preferred method of axillary staging in breast cancer. If metastases are detected, axillary node clearance (ANC) is necessary. Preoperative detection of nodal metastases using ultrasound-guided core biopsy (USCB) allows the surgeon to proceed directly to ANC. Negative CBs do not exclude metastases. All patients still need SLNB. However, by minimising false negatives, unnecessary SLNBs can be minimised. We compared our USCB results with the results of subsequent SLNB + axillary node sampling (ANS) or ANC to assess our accuracy.

**Methods** We performed a retrospective audit of patients having USCB in primary breast cancer. We included patients presenting to one consultant radiologist firm from our unit's symptomatic breast clinic between 27 March 2007 and 7 December 2010. Our criteria for CB included cortical thickness  $> 2$  mm, loss of fatty hilum and longitudinal axis/transverse axis  $< 2$ . We used a 14G Achieve needle to make four passes into the node.

**Results** Out of 41 CBs, on histology, eight were negative and 33 were positive. All positives were proven to be true positive at ANC. Seven out of eight negatives were found to be true negative (87.5% true negative) at SNB and ANS. One out of eight negative CBs was found to be false negative (12.5% false negative) requiring axillary clearance.

**Conclusion** We found that our results were comparable with published recent studies from the UK and abroad. Aggressive and more focused sampling could be suggested to further reduce false negatives.

#### P23

##### Dependence of detectability of microcalcification clusters on quality of mammography images

LM Warren<sup>1</sup>, A Mackenzie<sup>1</sup>, J Cooke<sup>2</sup>, R Given-Wilson<sup>3</sup>, M Wallis<sup>4</sup>,

D Chakraborty<sup>5</sup>, DR Dance<sup>1,6</sup>, KC Young<sup>1,6</sup>

<sup>1</sup>National Co-ordinating Centre for the Physics of Mammography, Guildford, UK; <sup>2</sup>Jarvis Breast Screening and Diagnostic Centre, Guildford, UK; <sup>3</sup>St

George's Healthcare NHS Trust, London, UK; <sup>4</sup>Cambridge University Hospitals

NHS Foundation Trust, Cambridge, UK; <sup>5</sup>University of Pittsburgh, PA, USA;

<sup>6</sup>University of Surrey, Guildford, UK

*Breast Cancer Research* 2011, 13(Suppl 1):P23 (doi: 10.1186/bcr2975)

**Introduction** This work compares the detection of microcalcification clusters (MC) in digital mammography images with different image quality levels.

**Methods** A total of 162 normal breast images were acquired on an a-Se DR system. MC clusters extracted from magnified images of sliced mastectomies were electronically inserted into half of the images. The majority of clusters used were subtle. All images were adjusted mathematically using a validated method to simulate the

appearance of images from a CR imaging system at the same dose and on both systems at half this dose. Seven experienced observers marked the location of suspicious regions, assigning a five-point score for confidence that the suspicious region was a cluster. The data were analysed using the area under the alternative free-response receiver operating characteristic (AFROC) and the area under the receiver operating characteristic (ROC) as figures of merit.

**Results** There was a significant reduction in detection using CR compared with DR; the AFROC area decreased from 0.83 to 0.63 and the ROC area decreased from 0.91 to 0.79 ( $P < 0.0001$ ). A significant reduction in detection was also evident at half the original dose for both DR and CR.

**Conclusion** The detection of subtle clusters was reduced significantly with CR compared with DR and it is possible that CR will miss cancers manifesting as microcalcification that would be found by DR. Calcification detection was sensitive to the dose used, which should be reflected in image quality standards to ensure adequate image quality is achieved even at the cost of a higher dose.

## P24

### Improving the validity of breast density assessment

A Eadie, P Whelehan, L Baker, J Berg, A Evans  
University of Dundee, UK

Breast Cancer Research 2011, 13(Suppl 1):P24 (doi: 10.1186/bcr2976)

**Introduction** As the importance of mammographic density in risk stratification and breast cancer research continues to grow, density assessment must be rigorous. Area-based human visual density assessment will continue until software is fully validated. Locally, having reviewed the literature, we chose two tools and sought to establish that these would give meaningful results in our hands for comparison with other data.

**Methods** In 50 mammograms, four observers each estimated the percentage dense area, recorded on a 100 mm visual analogue scale (VAS). On a separate occasion, each observer also assigned BIRADS density scores. The process was repeated with a minimum interval of 1 week. Observers were blinded to each others' scores and their own previous scores. Viewing parameters were standardised.

**Results** BIRADS Intra-rater agreement: Observers 1, 2 and 4, intraclass correlation coefficient (ICC) and lower 95% confidence bound all above 0.8 (excellent agreement); below 0.8 for Observer 3. Inter-rater: Observers 2 and 4, ICC = 0.97, 95% CI = 0.95 to 0.98; Observers 1 and 3 with any other, ICC below 0.8.

**Percentage** Intra-rater agreement, ICC for all observers >0.9 with lower confidence bound >0.8. Inter-rater: Observers 2 and 4 and 2 and 3, ICC and lower confidence bound >0.8; all other pairs, <0.8.

**Conclusion** Intra-observer and inter-observer agreement in mammographic density assessment varies. Percentage dense area estimation using a VAS appears more reproducible than the BIRADS classification. This simple study enabled selection of the most reliable observers and we recommend that other centres undertaking scientific studies where mammographic density is a relevant variable perform similar audits to maximise outcome measure validity.

## P25

### Can digital breast tomosynthesis offer an alternative to MRI in preoperative imaging of lobular carcinoma?

PD Wall<sup>1</sup>, JC Morel<sup>1,2</sup>, R Wasan<sup>1,2</sup>, D Evans<sup>1,2</sup>, C Peacock<sup>1,2</sup>, MJM Michell<sup>1,2</sup>  
<sup>1</sup>Kings College Hospital NHS Trust, London, UK; <sup>2</sup>South East London BSP, London, UK

Breast Cancer Research 2011, 13(Suppl 1):P25 (doi: 10.1186/bcr2977)

**Introduction** Digital breast tomosynthesis (DBT) is an emerging breast imaging technique which we have shown in our institution to more accurately size tumours when compared with 2D mammography. In this study we have looked at the accuracy of DBT in the sizing of invasive lobular carcinoma (ILC) when compared with MRI, the current imaging technique of choice.

**Methods** All clients diagnosed with ILC were identified between December 2008 and March 2010. Of these clients, those who had

undergone imaging with both MRI and DBT were extracted. Tumour diameter in the single largest dimension was recorded on DBT by two consultant radiologists. MRI and pathological tumours sizes were extracted from the notes. The agreement between the two imaging modalities and pathology was analysed using the methods described by Bland-Altman. Pearson correlation coefficients were calculated.

**Results** Twenty-three cases of lobular carcinoma were identified with MRI and DBT imaging. Pearson correlation coefficients for DBT with pathology  $r = 0.73$ , MRI with pathology  $r = 0.86$ , MRI with DBT  $r = 0.81$ . See Table 1.

Table 1 (abstract P25)

	DBT-pathology	MRI-pathology
Upper limit of agreement (mm)	31 (15 to 47)	25 (12 to 38)
Mean difference (mm)	-11 (-20 to -1)	-9 (-16 to -2)
Lower limit of agreement (mm)	-52 (-68 to -36)	-43 (-56 to -30)

95% CI presented in parentheses.

**Conclusion** The study shows that MRI is superior to DBT in predicting the histological size of lobular carcinoma although there is disparity with both techniques. With the advent of contrast-enhanced 2D mammography, we hope for the future development of contrast-enhanced DBT to give us a technique that will be comparable with MRI.

## P26

### Comparison of dedicated digital specimen radiography with direct digital specimen mammography images

JC Morel<sup>1,2</sup>, V Milnes<sup>1,2</sup>, A Iqbal<sup>1</sup>, MJ Michell<sup>1,2</sup>

<sup>1</sup>King's College Hospital NHS Trust, London, UK; <sup>2</sup>South East London BSP, London, UK

Breast Cancer Research 2011, 13(Suppl 1):P26 (doi: 10.1186/bcr2978)

**Introduction** The objective was to compare the image quality obtained from a dedicated specimen modality with the image quality from a standard direct digital mammography unit.

**Methods** All wide local excision (WLE), vacuum-assisted 10G core biopsy and 14G core biopsy samples were imaged with a Hologic Dimensions mammography unit and a Bioptics Biovision digital specimen radiography system. WLE specimens were imaged without magnification on both systems. Biopsy specimens were imaged with magnification. Two readers assessed each set of images. The number of microcalcifications was recorded and visibility of each lesion was assessed on a four-point scale.

**Results** The total number of specimens was 97. Of these specimens, 67 contained microcalcification, 23 masses, four distortions and three masses with calcification. In 44/67 specimens, the Biovision system demonstrated >20 microcalcifications as opposed to only 24/67 with the Hologic system; this is shown to be significant with  $P = 0.001$ . In two of the specimens no calcification was demonstrated on the Hologic system, whereas the Biovision system demonstrated <5 in these cases. A significant difference was also shown in the conspicuity of the lesions between the two systems, with the lesions having greater conspicuity on the Biovision system ( $P = 0.027$ ).

**Conclusion** Significantly more microcalcification is demonstrated by the Biovision system and conspicuity is significantly better. This provides increased confidence that a representative sample has been obtained at biopsy, and therefore increased diagnostic confidence.

## P27

### Cross-Atlantic differences in reading the same breast screening cases

Y Chen<sup>1</sup>, AG Gale<sup>1</sup>, MG Evanoff<sup>2</sup>, U Zakir<sup>1</sup>

<sup>1</sup>Loughborough University, Loughborough, UK; <sup>2</sup>American Board of Radiology, Tucson, AZ, USA

Breast Cancer Research 2011, 13(Suppl 1):P27 (doi: 10.1186/bcr2979)

**Introduction** American breast screening radiologists typically read a lower annual volume and recall more cases than their UK counterparts. This study investigated what happens when experienced breast



screening radiologists from both countries examined the same FFDM case set, albeit using different resolution displays.

**Methods** Sixteen experienced American breast screening radiologists interpreted 40 difficult FFDM cases containing various mammographic features, excluding small calcifications, using dual 20<sup>2</sup> DICOM calibrated monitors. For comparison purposes, the anonymous data were used of 16 experienced UK breast radiologists who had read the same cases as part of the PERFORMS scheme using clinical mammographic workstations.

**Results** The 16 American radiologists were split into two groups of low volume (<5,000 cases p.a.) and high volume (≥5,000 cases p.a.) and performances were compared. There was no significant differences ( $t = 0.23$ ,  $P > 0.05$ ). Consequently their performance data were combined and compared with those of the 16 UK radiologists. There was no significant difference between the two groups in correct recall decisions (UK, 97.1%; USA, 92.9%;  $t = 0.042$ ,  $P > 0.05$ ) although there were significant differences in correct return to screening decisions (UK, 88.9%; USA, 80%;  $t = 0.089$ ,  $P < 0.05$ ) and the number of malignancies detected (UK, 98.7%; USA, 93%;  $t = 0.049$ ,  $P < 0.05$ ).

**Conclusion** The use of lower resolution monitors (approximately half that of a mammographic workstation) by the American group was offset by their experience (>15 years) such that even very experienced but low-volume readers performed well. Whilst the UK group overall performed better on these cases, the American group still recalled more, reflecting their real-life screening criteria.

## P28

### TOMMY Trial (a comparison of tomosynthesis with digital mammography in the UK NHS breast screening programme) setting up a multicentre imaging trial

FJ Gilbert<sup>1</sup>, MGC Gillan<sup>1</sup>, MJ Michell<sup>2</sup>, KC Young<sup>3</sup>, HM Dobson<sup>4</sup>, J Cooke<sup>5</sup>, H Purushothaman<sup>6</sup>, YY Lim<sup>7</sup>, SM Astley<sup>8</sup>, SW Duffy<sup>9</sup>

<sup>1</sup>University of Aberdeen, UK; <sup>2</sup>King's College Hospital, London, UK; <sup>3</sup>NCCPM, Guildford, UK; <sup>4</sup>West of Scotland Breast Screening Service, Glasgow, UK;

<sup>5</sup>Jarvis Breast Screening Centre, Guildford, UK; <sup>6</sup>Barts & The London NHS Trust, London, UK; <sup>7</sup>University Hospital of South Manchester, Manchester, UK;

<sup>8</sup>University of Manchester, UK; <sup>9</sup>Barts and The London School of Medicine and Dentistry, London, UK

Breast Cancer Research 2011, 13(Suppl 1):P28 (doi: 10.1186/bcr2980)

**Introduction** Digital breast tomosynthesis (DBT) has the potential to improve the accuracy of standard digital mammography (DM) [1]. The TOMMY Trial is a multicentre, multireader, retrospective matched comparison of the diagnostic performance of DBT and DM.

**Methods** *Study population* Women (47 to 73 years old) recalled for further assessment after routine breast screening and women <50 years with a family history of breast cancer, attending annual mammographic screening. *Intervention* Women who consent to participate in the trial undergo standard two-view DM and DBT imaging of both breasts. Images are acquired in a single examination under the same degree of breast compression on a commercially available (Hologic) digital mammography system. *Outcome measures* The primary outcome measure is the relative sensitivity and specificity of DM and DBT in the detection of early-stage cancers and subtle lesions, particularly in women with dense breasts. This will be evaluated in a retrospective reading study where readers at each centre conduct blinded independent reviews of anonymised DM, or DBT, or DM and DBT images of cases from other centres.

**Results** The trial set-up has involved lengthy and complex legal negotiation with collaborating sites, the equipment manufacturer and the grant-awarding body. Designated readers from each centre have completed tomosynthesis training and recruitment has commenced.

**Conclusion** It should be noted that the negotiation of contracts and commercial agreements adds a considerable time burden to the set-up phase of multicentre trials.

#### Reference

1. Dobbins JT, Godfrey DJ: Digital X-ray tomosynthesis: current state of the art and clinical potential. *Phys Med Biol* 2003, 48:R65-R106.

## P29

### Detection of clinically and mammographically occult cancer by bilateral whole breast ultrasound: experience from a district general hospital

TR Rehman, B Upadhyay, L Kanagarajah

Basildon and Thurrock University Hospital, Basildon, UK

Breast Cancer Research 2011, 13(Suppl 1):P29 (doi: 10.1186/bcr2981)

**Introduction** Although ultrasound is considered to be a poor screening tool, it is reported to be useful in detecting multifocal cancers [1]. This study aims to look at the use of bilateral whole breast ultrasound in detecting clinically and mammographically occult breast cancers.

**Methods** All patients presenting to symptomatic clinic in Basildon Hospital underwent sonographer-performed bilateral whole breast ultrasound before the year 2010. All breast cancer patients in 2009 whose imaging details are available on the Radiology Management System (RMS) and PACS are the materials of this study (number of patients: 101). Clinical and imaging details were evaluated on RMS and PACS and cases in which cancer was detected only by ultrasound were identified.

**Results** Among the 101 patients, multifocal cancers were detected in ipsilateral breast in two patients. Both of these patients had one clinically and mammographically detected cancer. The second smaller lesion was depicted only on ultrasound. Apart from the above multifocal cancers, there was no case in which cancer was identified only on ultrasound.

**Conclusion** Operator-performed bilateral whole breast ultrasound is useful in detecting multifocal primary breast cancer although its routine use in all the patients is yet to be proven.

#### Reference

1. Wilkinson LS, Given-Wilson R, Hall T, Potts H, Sharma AK, Smith E: Increasing the diagnosis of multifocal primary breast cancer by the use of bilateral whole-breast ultrasound. *Clin Radiol* 2005, 60:573-578.

## P30

### Can mammographic features predict invasive carcinoma at screening assessment?

ND Forester, P Burrows, A-M Wason

Pennine Breast Unit, St Luke's Hospital, Bradford, UK

Breast Cancer Research 2011, 13(Suppl 1):P30 (doi: 10.1186/bcr2982)

**Introduction** In our institution, 30% of screen-detected DCIS diagnosed by 14G core biopsy will be upgraded to invasive carcinoma at definitive surgery, necessitating subsequent sentinel node procedure to complete staging. This could be decreased by first-line large-bore vacuum-assisted biopsy. Prior to introducing this, we reviewed patient factors, aiming to identify subsets of patients who may benefit from first-line vacuum-assisted biopsy.

**Methods** A retrospective review of B5a diagnoses at initial biopsy, April 2009 to March 2010. Univariate and multivariate logistic regression analysis was performed to analyse the impact of patient, radiographic and histological factors on the B5b upgrade rate.

**Results** A total of 51 patients had DCIS diagnosed on initial core biopsy. Fifteen were upgraded to invasive carcinoma following surgical excision. No association between patient age, screening round, grade of DCIS, calcification pattern (focal vs. diffuse) and ER/PR status was found. Mammographic calcification size did significantly predict upgrade in univariate analysis (OR = 1.04 per mm increase in size of calcification; 95% CI = 1.01 to 1.07;  $P = 0.02$ ) and in multivariate analysis when adjusting for patient age and calcification pattern (OR = 1.04; 95% CI = 1.00 to 1.07;  $P = 0.043$ ). Stratification of mammographic calcifications showed that clusters >20 mm in size have 16.6 times the odds of upgrade compared with calcifications <10 mm (95% CI = 1.38 to 200.02;  $P = 0.027$ ).

**Conclusion** Size of calcifications on mammography is a significant predictor of upgrade to invasive carcinoma. Increases in calcification of 10 mm increase the odds of upgrade to invasive carcinoma by 34%. Given the significantly increased upgrade rate for calcifications over 20 mm, first-line vacuum-assisted biopsy in this subset of patients at initial screening assessment may prove cost-effective.

**P31**

**Role of MRI as a problem-solving tool in screening assessment**

RK Locke, G Rubin

Park Centre for Breast Care, BSUH NHS Trust, Brighton, UK

Breast Cancer Research 2011, 13(Suppl 1):P31 (doi: 10.1186/bcr2983)

**Introduction** In the UK, MRI is mostly used to stage needle biopsy proven cancer. Less often it is used in problem-solving when there is no proven malignancy. We reviewed its use as a problem-solver after mammographic screening.

**Methods** NHS screening patients who attended assessment between December 2008 and July 2011 and had contrast-enhanced MRI within 3 months were identified. Fourteen out of 47 did not have the MRI as staging, and were reviewed.

**Results** (1) Mammography, ultrasound and/or core biopsy pathology were felt to be discordant in seven cases. MRI confidently excluded malignancy in five. Two had surgery, finding a complex sclerosing lesion in one and a reactive lymph node in the other. (2) Clinical concern was not matched by mammography and ultrasound in four cases. MRI confidently excluded malignancy in three but found an otherwise occult cancer in the fourth. (3) Core biopsies were technically difficult in two cases. MRI confidently excluded malignancy in one and the other was benign on excision. (4) One patient had proven cancer in one breast not needing staging. Screening also showed microcalcifications with a possibly nonrepresentative normal core biopsy in the other breast. MRI was suspicious and this was also cancer at diagnostic surgery.

**Conclusion** MRI, used selectively, was useful in problem-solving at screening assessment. When it was negative, this meant some patients could be reassured without surgery. It was useful where there was clinical suspicion but normal conventional imaging.

**P32**

Abstract withdrawn by author.

**P33**

**Preoperative sonographic axillary staging in breast cancer: correlation with sentinel node sampling**

P Sankaye, S Chhatani, S Doyle, J Steel, K Paisley, B Lyons, R Watkins, G Porter

Plymouth Hospitals NHS Trust, Plymouth, UK

Breast Cancer Research 2011, 13(Suppl 1):P33 (doi: 10.1186/bcr2985)

**Introduction** Axillary ultrasound staging with core biopsy (CB) or fine needle aspiration (FNA) in primary breast cancer is well established. Negative patients will have a sentinel lymph node biopsy (SLNB). This study compares the initial ultrasound finding versus final axillary histology in patients undergoing SLNB.

**Methods** A total of 249 breast carcinoma patients, who underwent SLNB between August 2007 and January 2011, were included. Axillary ultrasound and histology results were reviewed. Ultrasound findings and any subsequent biopsies were recorded in positive and negative SLNB groups. The axillary lymph node biopsy histology slides were reviewed in the false negative axillary ultrasound biopsy/FNA group.

**Results** Of 249 patients, 191 (76.7%) were SLNB-negative and 58 (23.3%) were SLNB-positive. Thirty out of 191 (16%) patients without axillary metastases had ultrasound-guided sampling. Two out of 191 did not have ultrasound-guided sampling as the procedure was deemed unsafe. Twelve out of 58 (21%) SLNB-positive patients had abnormal ultrasound appearances; 8/12(67%) had CB and 4/12 (33%) had FNA, not significantly different to the CB/FNA rates in SLNB-negative patients (24/32 (75%) and 6/32 (25%), respectively;  $P = 0.2$ ). See Figure 1. Review of 12 false negative histology slides revealed 1/12 (8%) had micrometastasis and 11/12 (92%) were benign.

**Conclusion** There are no significant differences in the rate of axillary ultrasound abnormality between SLNB-positive and SLNB-negative patients. This suggests that ultrasound nodal abnormalities due to malignancy are probably being diagnosed by ultrasound-guided sampling and do not progress to SLNB. It also supports SLNB for sonographically abnormal lymph nodes as opposed to axillary nodal dissection, as many of these patients will not have metastases, if USS sampling is negative. Our small study has not shown significant benefit of CB over FNA in axillary staging. We found a low upgrade rate on reviewing original ultrasound-guided histology slides, supporting current pathology techniques.

**P34**

**Quantification of the UK five-point breast imaging classification and mapping to BI-RADS: to facilitate comparison of reporting, research and published literature**

KTaylor, PD Britton, S O'Keefe, MG Wallis

Cambridge University Hospitals NHS Foundation Trust, Cambridge, UK

Breast Cancer Research 2011, 13(Suppl 1):P34 (doi: 10.1186/bcr2986)

**Introduction** The Royal College of Radiologists Breast Group has formalised the UK five-point breast imaging scoring system to encourage uniformity of reporting. The Breast Imaging and Reporting Data System (BI-RADS) is widely used throughout North America and Europe, and, unlike the UK scoring system, each BI-RADS category has an associated cancer likelihood. This study aims to quantify the cancer likelihood of each of the UK categories and map them to comparable BI-RADS categories to facilitate comparison of reporting, research and literature.

**Methods** Between January 2001 and December 2008, mammograms and ultrasounds performed in a symptomatic setting were prospectively UK scored and the percentage of cancer outcomes within each group calculated. These were then compared with the percentage incidence of the BI-RADS categories.

**Results** Of 23,741 separate assessment episodes, 15,288 mammograms and 10,642 ultrasound examinations were evaluated. There was direct correlation between UK scoring and BI-RADS for categories 1 and 5. UK score 2 lipomas and simple cysts correlated with BI-RADS 2, with the remaining UK score 2 lesions (mostly fibroadenomas) assigned to BI-RADS 3. BI-RADS 4 incorporates a wide range of cancer risk (2 to 95%) with subdivisions a, b and c indicating increasing, but unspecified, likelihood of malignancy. UK score 3 correlated with BI-RADS 4 a/b and UK score 4 corresponded with BI-RADS 4c.

**Conclusion** The cancer likelihood of the UK scoring has been quantified and mapped to the appropriate BI-RADS categories with equivalent

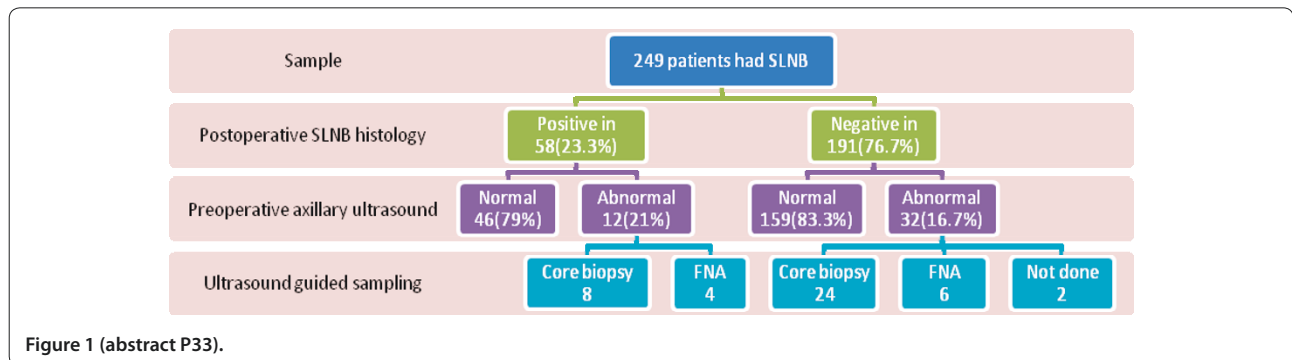


Figure 1 (abstract P33).

cancer risks. This facilitates the sharing of UK research data and clinical practice on an international scale.

### P35

#### Impact of presurgical breast MRI in a district general hospital

A Newland, M Dumba, S Flais

Ealing Hospital, London, UK

Breast Cancer Research 2011, 13(Suppl 1):P35 (doi: 10.1186/bcr2987)

**Introduction** Routine MRI in the assessment of lobular carcinoma, invasive ductal carcinoma in dense breasts, patients younger than 35 or radioclinical discordance at the time of cancer diagnosis was introduced in the symptomatic breast unit of Ealing Hospital in 2009. We analyse the impact of this new pathway on our local practice.

**Methods** All patients with a new diagnosis of breast cancer in two periods of 18 months, before and after the introduction of MRI, were reviewed. Mastectomy rates were compared between the two groups and the role of MRI in this change is discussed. The cost of the new pathway is reviewed, including the cost of additional imaging and biopsies generated by MRI.

**Results** The mastectomy rate increased from 25% between 1 January 2006 and 30 June 2007, to 40% between 1 January 2010 and 30 June 2011. Other factors (patient group, cancer grade, multidisciplinary team decision-making process) were unchanged. The cost of the presurgical assessment of patients undergoing MRI has increased significantly.

**Conclusion** Presurgical MRI has changed the first-line treatment offered by our team, but at a significant cost, especially for the radiology department. The local impact on overall survival and event-free survival is still unknown.

### P36

#### Should general practitioner access to breast imaging and 2WW co-exist?

ME Fletcher, N Sharma, BG Dall

Leeds Teaching Hospital NHS Trust, Leeds, UK

Breast Cancer Research 2011, 13(Suppl 1):P36 (doi: 10.1186/bcr2988)

**Introduction** The Leeds breast service treats over 500 breast cancers a year. The general practitioners (GPs) have always had access via the one-stop breast clinic or direct access to the imaging department. Any positive imaging findings are actioned within imaging and the patients are referred to the clinic for results. The GP is informed. With the introduction of 2WW it is appropriate to re-audit this practise.

**Methods** This is a retrospective audit performed over a 6-month period using the radiology database (CRIS) and the clinical database (PPM). The data collected included the number of GP referrals, the imaging performed, the number of biopsies and the number of referrals to the breast clinic. The timeline for each patient was recorded and the costs involved where compared with referral to the one-stop clinic.

**Results** A total of 592 patients were referred direct to imaging from 1 July 2010 to 31 December 2010. The GP referrals were seen within an average of 23 days (3 to 47 days). A total of 223 patients had mammography and ultrasound, 165 had mammography only and 204 had ultrasound only. Twenty-six patients had biopsies; 45% were performed at the same attendance. Nine cancers were diagnosed. Forty-one patients were referred to the one-stop clinic. The radiology department received payment per procedure compared with a standard percentage per patient.

**Conclusion** The one-stop clinic with triple assessment is the gold standard. GP direct access still safely reduces the burden of a 2-week wait provided robust pathways are in place to ensure prompt biopsy and appropriate referral to the breast clinic.

### P37

#### Size matters

M Powell, B Bayley

Breast Test Wales, Wrexham, UK

Breast Cancer Research 2011, 13(Suppl 1):P37 (doi: 10.1186/bcr2989)

**Introduction** It is accepted that a proportion of patients treated by breast-conservation surgery for unifocal malignancy will undergo further surgery for residual disease. Preoperative planning for

impalpable lesions involves a radiological prediction of the extent of disease. The optimal outcome is disease clearance achieved by one operation only. We have revisited our cases which required a subsequent theatre visit in order to facilitate an understanding of the factors involved in accurate lesion sizing and thereby reduce re-excision rates.

**Methods** All women screened through the Wrexham centre with a positive diagnosis of *in situ* or invasive disease going on to have operative treatment over a 1-year period have been included. The lesions were double-read by experienced film readers to obtain a maximal dimension on two-view mammography and ultrasound where applicable. Each case was attributed a grading, 1 to 3, for ease of measurement. This was compared with the postoperative histology, reported by a specialist breast histopathologist. The size, type, grade, receptor status and nodal status were recorded for each case.

**Results** A total of 61 cases were selected. The preoperative prediction of size was closest to the mammographic measurement in 74% of cases, and to the ultrasound dimension in 21%. The remainder showed equal measurements on both.

**Conclusion** The mammogram provides a more accurate prediction of lesion size when compared with ultrasound images. It should be borne in mind that a certain proportion of women will choose mastectomy over conservation regardless of the available option of conservation.

### P38

Abstract withdrawn by author.

### P39

#### Should we be using nonscreening symptomatic units' mammogram machines for screening? Women's attitudes and factors likely to affect whether they attend

EF Jones<sup>1,2</sup>, C Zammit<sup>1,3</sup>, G Rubin<sup>3</sup>

<sup>1</sup>Brighton and Sussex Medical School, Brighton, UK; <sup>2</sup>Guy's and St Thomas's

NHS Foundation Trust, London, UK; <sup>3</sup>Brighton and Sussex University Hospitals, Brighton, UK

Breast Cancer Research 2011, 13(Suppl 1):P39 (doi: 10.1186/bcr2991)

**Introduction** Symptomatic mammogram machines in trusts that do not run screening services are rarely used by the National Breast Screening Service. This is a potential untapped site for screening. This study surveyed whether women attending current screening sites would go to hospital-based symptomatic units instead.

**Methods** All women who attended NHS breast screening in five different sites in South East England were surveyed over 1 day. One site was at the screening centre. The others were mobile, two being rural and two urban. Home postcodes were used to calculate how far women had travelled and the distance to the nearest symptomatic unit. This was correlated with a questionnaire about mode of transport and whether the women would be ready to attend screening at a symptomatic unit.

**Results** Women at four of the sites said they would just as likely to attend their local hospital for screening. This included one of the rural sites, where the average women would have had to travel no further to her local hospital. The fifth site was also rural but here most women would have to travel more than 15 miles to the hospital, and most had travelled less than 5 miles to the mobile unit. One woman in three would be less likely to attend screening at the local hospital than this site.

**Conclusion** Women going for screening would be happy to have this in their local hospital symptomatic unit as long as this did not entail extra travel.

### P40

#### Occult breast carcinoma presenting with axillary lymphadenopathy

MA Crotch-Harvey

Macclesfield District General Hospital, Macclesfield, UK

Breast Cancer Research 2011, 13(Suppl 1):P40 (doi: 10.1186/bcr2992)

**Introduction** Occult breast carcinoma presenting with axillary lymphadenopathy is an uncommon but difficult clinical problem. The

most appropriate diagnostic pathway, the prognosis and the best form of treatment may be uncertain. To answer these questions, we have examined the outcomes of women presenting in this way over a number of years.

**Methods** Thirteen women were identified prospectively over a 12-year period, presenting with suspicious lymphadenopathy but no identifiable breast tumour on initial mammography or ultrasound. Biopsy of the abnormal nodes was consistent with a breast primary in all cases. All women had further imaging with breast MRI (11 cases), breast scintigraphy (one case) and CT scanning of the chest and abdomen. Second-look ultrasound was targeted to suspicious areas identified on second-line imaging. The type of treatment, presence of distant metastases and survival were recorded.

**Results** Further imaging revealed a primary breast lesion in seven cases, six remained truly occult. Follow-up ranged from 3 to 144 months (mean 38 months). Three patients died, one is alive with distant metastases and nine remain disease free. Those with no identifiable primary were treated with chemotherapy usually in combination with radiotherapy.

**Conclusion** The use of MRI and targeted ultrasound-guided biopsy revealed primary tumours in approximately half our cases presenting with lymphadenopathy and negative conventional imaging. Chemotherapy with radiotherapy appears to be an effective treatment for occult breast cancer. The initial staging tests are crucial and if clear the prognosis appears similar to patients with breast cancer and positive axillary nodes.

#### P41

##### MRI characteristics of lobular carcinoma of the breast

A Leaver, G Bristow, A Redman, J Potterton  
Gateshead Health NHS Foundation Trust, Gateshead, UK  
Breast Cancer Research 2011, 13(Suppl 1):P41 (doi: 10.1186/bcr2993)

**Introduction** Lobular carcinoma is frequently atypical on conventional imaging. MRI has increasingly been used to evaluate lobular carcinoma in recent years. Our experience has been that lobular MRI findings are also relatively difficult to interpret. In this study we aim to define lobular MRI characteristics to aid preoperative staging accuracy.

**Methods** This retrospective study included all lobular breast cancers which were subjected to preoperative MRI in our Trust from May 2010 to May 2011. Radiologists blinded to the original MRI reports used a questionnaire based on BIRADS to describe the findings. Final surgical histology was used as the gold standard for comparison. Descriptive statistics were performed on data obtained.

**Results** Full imaging and final surgical histology was available for 24 ladies with lobular carcinoma. In 83% (20/24) of cases the MRI tumour morphology was of a mass (19/20 irregular mass). Mass enhancement varied: heterogeneous 50% (10/20), homogeneous 40% (8/20). MRI 3D reconstruction gave the largest measurement most frequently (11/24), but the third post-contrast sequence most frequently (8/24) provided the most accurate tumour measurement. Enhancement curves were type 2 in 15/24 cases. In 21/24 cases the question of MRI multifocality correlated with final surgical histology. A total of 12.5% (3/24) patients had contralateral lesions identified by MRI.

**Conclusion** The most common lobular cancer morphology on MRI is an irregular mass with heterogeneous, type 2 enhancement. When compared with surgical histology, the third post-contrast (coronal) sequence gave the most accurate tumour measurement most frequently, with 3D reconstruction providing an overestimate in some cases.

#### P42

##### Extended opening hours of the one-stop shop

S Flais, M Dumba, A Newland  
Ealing Hospital, London, UK  
Breast Cancer Research 2011, 13(Suppl 1):P42 (doi: 10.1186/bcr2994)

**Introduction** The one-stop model was introduced into the oncology follow-up clinic for breast cancer patients at Ealing Hospital in November 2010. We present why and how this change was introduced,

and assess the impact on radiology practice during the first 6 months. We also present the results of our first patient satisfaction survey completed by those attending the new clinic.

**Methods** A customer survey was completed by 50 patients attending the new follow-up clinic over a 2-month period. The impact on radiology practice was also assessed

**Results** A total 100% of patients preferred the new follow-up system, and organisational changes to the work flow were implemented with no significant additional cost.

**Conclusion** The one-stop approach is preferred by breast cancer patients at all stages of their care, not just at diagnosis. Patients can benefit from this system with minimal additional cost burden.

#### P43

##### Use of ultrasound elasticity imaging to monitor the response of a primary breast cancer to neoadjuvant chemotherapy in one patient in a pilot study

RE English<sup>1</sup>, A Di Battista<sup>2</sup>, RF Adams<sup>1</sup>, L Winter<sup>1</sup>, JA Noble<sup>2</sup>  
<sup>1</sup>Oxford Radcliffe Hospitals NHS Trust, Oxford, UK; <sup>2</sup>Oxford University, Oxford, UK  
Breast Cancer Research 2011, 13(Suppl 1):P43 (doi: 10.1186/bcr2995)

**Introduction** Neoadjuvant chemotherapy is used as the primary treatment for locally advanced breast cancer to reduce tumour size and protect against metastatic spread. Monitoring the response to chemotherapy is achieved mainly by clinical assessment, which may prove unsatisfactory. This proof-of-principle study is to determine if changes of size and texture in the elastogram can track tumour response.

**Methods** A young woman with an invasive ductal carcinoma, visible on mammography and ultrasound (US), was treated with seven cycles of chemotherapy. Diagnostic mammography, MRI and core biopsy studies were performed. B-mode US and elastography datasets were collected in two planes prior to each cycle using a coarse calcification within the tumour as a constant reference point. Seven sequential strain images, each 3 weeks apart, were collected in total. The ratio of tissue strain within and outside the mass was calculated as an indicator of tumour response. The findings were compared with the post-chemotherapy MRI and mastectomy histology.

**Results** The tumour showed almost complete histological response to chemotherapy. Sequential elastography studies demonstrated significant ratio changes in stiffness in tumour and peritumoural areas.

**Conclusion** Preliminary results suggest the changes in tumour and peritumour stiffness caused by chemotherapy are detectable by ultrasound elastography. Further investigation is required to evaluate the potential of elastography as a monitoring tool for chemotherapy treatment.

#### P44

##### Assessment of patient doses during mammography practice at Kenyatta National Hospital

JS Wambani<sup>1</sup>, GK Korir<sup>2</sup>, MN Shyanguya<sup>1</sup>, IK Korir<sup>3</sup>  
<sup>1</sup>Kenyatta National Hospital, Nairobi, Kenya; <sup>2</sup>University of Massachusetts Lowell, MA, USA; <sup>3</sup>National Nuclear Regulator, Johannesburg, South Africa  
Breast Cancer Research 2011, 13(Suppl 1):P44 (doi: 10.1186/bcr2996)

**Introduction** Breast cancer constitutes 21% of all cancer cases and ranks third according to cancer type in Kenya. Mammography therefore remains a powerful radiographic imaging technique for detecting and managing breast cancer. However, the active and radiosensitive glandular tissue calls for the need for an effective quality assurance programme.

**Methods** A questionnaire method was developed and used in recording the displayed patient dose, compressed breast thickness and exposure factors. The average glandular dose, device performance, and film quality grading were also carried out at the largest mammography facility in Kenya.

**Results** There were 3,264 films from 1,252 women of between 25 and 90 years old. The AGD per film was 2.14 (range 0.27 to 9.43) mGy for the CC projection and 2.44 (range 0.20 to 10.12) mGy for the MLO

projection. A total 17% of CC and 30% of MLO films recorded doses above the recommended 3 mGy diagnostic reference level.

**Conclusion** In view of the diagnostic dose finding of this study, the variation of mammography imaging techniques revealed the need for standards and optimisation of mammography practice in Kenya.

#### P45

##### Mammography as a diagnostic tool in women aged 35 to 39 presenting to the symptomatic breast clinic

J Long, CE Richardson, J Barrett, C Deacon, P Matey  
The Royal Wolverhampton Hospitals NHS Trust, Wolverhampton, UK  
Breast Cancer Research 2011, 13(Suppl 1):P45 (doi: 10.1186/bcr2997)

**Introduction** Recent guidelines advise that mammography should only be offered to women between the ages of 35 and 39 if clinical examination raises concern or a targeted ultrasound of the breast reveals a suspicious abnormality [1]. The aim of this study was to assess the role of mammography as a diagnostic tool in women aged 35 to 39 presenting to the symptomatic breast clinic.

**Methods** All women aged between 35 and 39 years presenting to the symptomatic breast clinic between April 2010 and March 2011 were eligible for inclusion. Data were collected on demographics, presenting symptoms, radiological investigation and diagnosis.

**Results** A total 112 of 124 women identified had mammography performed as part of their initial assessment; one woman presented with a solid lump which was indeterminate on ultrasound but proved to be breast cancer on biopsy. The majority of patients were diagnosed with mastalgia, benign nodularity or fibroadenoma. Core biopsies confirmed benign pathology in eight women. Of the 12 women who did not have mammography, benign pathology was diagnosed using clinical examination and ultrasound, with breast cysts and sepsis being the commonest causes of pathology.

**Conclusion** The role of mammography in women aged 35 to 39 presenting to the symptomatic breast clinic should be reassessed. Our data support the guidelines that ultrasound is the imaging method of choice in this age group.

##### Reference

1. Willett AM, Michell MJ, Lee MJR, editors: *Best Practice Diagnostic Guidelines for Patients Presenting with Breast Symptoms*. Department of Health; November 2010 [http://www.associationofbreastsurgery.org.uk/Content/Guidelines.aspx].

#### P46

##### What pathology is an indication for vacuum-assisted biopsy?

WMV Shuen<sup>1</sup>, RJ Currie<sup>2</sup>  
<sup>1</sup>Peninsula Radiology Academy, Plymouth, UK; <sup>2</sup>Royal Devon & Exeter NHS Foundation Trust, Exeter, UK  
Breast Cancer Research 2011, 13(Suppl 1):P46 (doi: 10.1186/bcr2998)

**Introduction** Vacuum-assisted biopsies (VABs) are used for both diagnostic and treatment purposes. Currently there are no set guidelines in our department as to who should proceed to a VAB. The purpose of this study is to analyse the indication for a VAB, the upgrade or downgrade rate when compared with the initial core biopsy and the overall final outcome of these patients.

**Methods** A retrospective search of all VABs performed from 1 April 2009 to 31 March 2010 was identified. The indication for VAB, the initial core biopsy results and the vacuum biopsy results and final outcomes were recorded.

**Results** A total of 37 VABs were performed within the year. Two were for treatment excision of fibroadenoma. A total of 35 were diagnostic VABs. Three went straight to vacuum biopsies due to either a small lesion or suspicion for a recurrent malignancy. Of the remaining 32 cases, 21 were for indeterminate M3/U3/B3 lesions, five for clinical and pathological mismatch, three for further clarification of core biopsy result, two for staging the extent of the tumour, and one for inadequate core biopsy. Thirteen out of 32 (40.6%) were upgraded from the initial biopsy, 10 proceeded to further procedures. Six out of 32 (18.8%) remained the same grade, two (33.3%) required further procedure. Thirteen out of 32 (40.6%) were downgraded, five (38.5%) proceeded to further procedures.

**Conclusion** Our audit has shown VAB is useful in providing a definitive diagnosis in a range of breast pathology, in particular B3 lesions. We therefore strongly advise its use in cases of pathological uncertainty to save patients from further unnecessary interventions.

#### P47

##### Assessment of the axilla in primary operable breast carcinoma

M Twomey, S Hayes, TJ Browne, L Duddy, P Smiddy  
Cork University Hospital, Wilton, Cork, Ireland  
Breast Cancer Research 2011, 13(Suppl 1):P47 (doi: 10.1186/bcr2999)

**Introduction** The purpose of this study was to analyse assessment of the axilla in patients with primary operable breast cancer in a one-stop symptomatic breast unit.

**Methods** A retrospective review of 229 patients diagnosed with new primary operable breast carcinoma over a 12-month period. All patients underwent axillary ultrasound (US). All cases with normal US had subsequent sentinel lymph node biopsy (SLNB). All cases with abnormal US underwent fine needle aspiration cytology (FNAC). Findings were correlated with SLNB and axillary node clearance histology.

**Results** A total of 128 patients had normal US and subsequent SLNB, this was positive in 29 (23%); 12 (40%) had micro metastases; primary tumour size was >2 cm in 22 (76%). Positive predictive value for US and FNAC was 97%. Negative predictive value was 75%. False positive and negative rates for US axilla are discussed with analysis of tumour subgroups and pattern of positive nodes.

**Conclusion** The combination of US and FNAC is a powerful predictive tool of axillary disease [1]. Disappointingly false negative axillary US did not correlate solely with micro metastases. This may reflect a learning curve effect, and will be reassessed on follow-up data.

##### Reference

1. Alvarez S, et al.: Role of sonography in the diagnosis of axillary lymph node metastases in breast cancer: a systematic review. *Am J Radiol* 2006, 186:1342-1348.

Cite abstracts in this supplement using the relevant abstract number, e.g.:

Twomey M, et al.: Assessment of the axilla in primary operable breast carcinoma [abstract]. *Breast Cancer Research* 2011, 13(Suppl 1):P47.