

## MEETING ABSTRACTS

# Royal College of Radiologists Breast Group Annual Scientific Meeting 2010

Brighton, UK. 1–2 November 2010

Published: 25 October 2010

### ORAL PRESENTATIONS

#### O1

##### Validation of a new automated volumetric breast density measurement system as a marker of breast cancer risk

K Pinker<sup>1,2</sup>, N Perry<sup>2</sup>, S Milner<sup>2</sup>, K Mokbel<sup>2</sup>, S Duffy<sup>3</sup>

<sup>1</sup>Department of Radiology, Division of Molecular and Gender Imaging, Medical University Vienna, Austria; <sup>2</sup>Princess Grace Hospital, The London Breast Institute, London, UK; <sup>3</sup>Wolfson Institute, Queen Mary College, University of London, UK  
*Breast Cancer Research* 2010, **12**(Suppl 3):O1 (doi: 10.1186/bcr2648)

**Purpose** To validate the predictive power for determining breast cancer risk of an automated breast density measurement system with full-field digital mammography (FFDM).

**Materials and methods** Two hundred cancers and 200 controls were imaged with FFDM. Density was measured separately on MLO and CC images using an integral automated volumetric breast density measurement system (Hologic, Quantra). For each cancer, the contralateral mammogram was used. Each cancer was matched to a control case by date of birth, age at examination and laterality of mammogram used for density determination. Breast density (percentage of fibroglandular tissue) was analyzed by Quantra. Data were analyzed by conditional logistic regression to determine the effect on breast cancer risk.

**Results** The percentage of breast density ranged from 6% to 63%. Density declined significantly with age ( $P < 0.001$ ). Overall, there was no significant association of density with risk of breast cancer ( $P = 0.4$ ). There was a suggestive increase in risk with dense volume higher than 35% (OR = 1.80, 95% CI = 0.96 to 3.39,  $P = 0.07$ ). There was significant heterogeneity by age in the effect of density on risk ( $P = 0.04$ ). In women aged <50, density was significantly associated with increased risk ( $P = 0.02$ ), with odds ratios of 6.06, 3.98 and 10.59 for density volumes of 15 to 24%, 25 to 34% and  $\geq 35\%$  respectively, relative to those with <15%. In women aged  $\geq 50$  years there was no association of density with risk ( $P = 0.5$ ).

**Conclusions** Quantra automated volumetric breast density measurement is strongly associated with breast cancer risk in women aged under 50, but not in women aged  $\geq 50$  years or over.

#### O2

##### Ultrasound elastography as an adjuvant to conventional ultrasound in the preoperative assessment of axillary lymph nodes in suspected breast cancer: a pilot study

K Taylor<sup>1</sup>, S O'Keefe<sup>1</sup>, GM Treece<sup>2</sup>, R Sinnatambay<sup>1</sup>, PD Britton<sup>1</sup>, MG Wallis<sup>1</sup>

<sup>1</sup>Cambridge University Hospitals NHS Foundation Trust, Cambridge, UK; <sup>2</sup>Department of Engineering, Cambridge University, Cambridge, UK  
*Breast Cancer Research* 2010, **12**(Suppl 3):O2 (doi: 10.1186/bcr2649)

**Introduction** NICE guidelines recommend conventional ultrasound (CU) of the axilla as preliminary staging in patients with breast cancer. However, up to one-third of nodes showing normal morphology are metastatic on surgical histology [1]. Ultrasound elastography (UE) uses received

radiofrequency data to produce an elastogram depicting tissue stiffness. UE has been researched in the breast but there are no published data regarding UE of the axilla.

**Methods** Fifty women attending the breast unit as symptomatic GP referrals with breast lesions sonographically suspicious of breast cancer underwent UE of the axilla simultaneously with routine CU examination. Elastograms were visually scored, strain measurements calculated and nodal perimeter and area measurements recorded. UE was compared with CU with histology as the reference standard.

**Results** Twenty-nine nodes were histologically normal, 21 were metastatic. Normal nodes were indistinguishable from surrounding tissue on UE. Using cut-off points for biopsy selected for the study, sensitivity was 90% for UE visual scoring, 100% for strain scoring and 76% for CU. Specificities were 86%, 48% and 78% respectively. ROC analysis yielded AUC values of 0.9 for UE visual scoring, 0.86 for strain scoring and 0.82 for CU. There was no significant difference between any area and perimeter measurements.

**Conclusions** UE can demonstrate axillary lymph nodes and differentiate benign from malignant nodes. UE visual scoring shows greatest promise in improving yield without excessive benign biopsies.

#### Reference

1. Britton P, *et al*: Use of ultrasound guided axillary node core biopsy in staging of early breast cancer. *Eur J Radiol* 2009, **19**:561-569.

#### O3

##### Size matters: second breast cancer size following treatment for primary cancer as a predictor of survival

GS MacLennan<sup>1</sup>, G Lawrence<sup>2</sup>, C Boachie<sup>1</sup>, SD Heys<sup>3,4</sup>, FJ Gilbert<sup>4</sup>

<sup>1</sup>Health Services Research Unit, University of Aberdeen, UK; <sup>2</sup>West Midlands Cancer Intelligence Unit, Birmingham Women's NHS Foundation Trust, Birmingham, UK;

<sup>3</sup>Division of Applied Medicine, School of Medicine and Dentistry, University of Aberdeen and Aberdeen Royal Infirmary, NHS, Aberdeen, UK; <sup>4</sup>Aberdeen Biomedical Imaging Centre, University of Aberdeen and Aberdeen Royal Infirmary, NHS Grampian, Aberdeen, UK

*Breast Cancer Research* 2010, **12**(Suppl 3):O3 (doi: 10.1186/bcr2650)

**Introduction** The purpose of surveillance mammography following primary breast cancer treatment is to detect subsequent cancers at the smallest size. We examined the prognostic effect of size of ipsilateral breast tumour recurrence (IBTR) and metachronous contralateral breast cancer (MCBC) to assess potential benefit of surveillance mammography after breast cancer treatment.

**Methods** Second cancers (IBTR  $n = 1,174$ , MCBC  $n = 975$ ) diagnosed between 1 January 1990 and 31 January 2007 from the West Midlands Cancer Intelligence Unit Breast Cancer Registry were analysed. Survival from diagnosis of second cancer was examined using Cox regression models. Risk factors included were prognostic factors of the primary tumour and size of the second tumour. Outcomes were time to all-cause death and to breast cancer death. Estimates are hazard ratios (HRs) and 95% confidence intervals.

**Results** There were 613 all-cause deaths and 422 breast cancer deaths after IBTR. For both outcomes, second cancers >2 cm had poorer prognosis compared with those <1 cm, HRs were 1.75 (1.29 to 1.37) and 1.99 (1.37 to 2.89). In MCBC there were 358 all-cause deaths, HR 2.14 (1.49 to 3.06), and 23 breast cancer deaths, HR 1.99 (1.38 to 2.83).

**Conclusions** With either IBTR or MCBC the size of the second tumour is important, patients with cancers >2 cm in diameter being at a significantly greater risk of death. Lead-time bias from the mode of detection may be a factor in these results. The frequency of surveillance mammography should be considered for maximum benefit.

#### O4

##### Reduced breast biopsy rates with a combined high temporal and high spatial resolution MR imaging protocol at 3 Tesla

K Pinker<sup>1</sup>, W Bogner<sup>2</sup>, S Gruber<sup>2</sup>, G Grabner<sup>2</sup>, S Trattning<sup>2</sup>, TH Helbich<sup>1</sup>

<sup>1</sup>Department of Radiology, Division of Molecular and Gender Imaging, Medical University Vienna, Austria; <sup>2</sup>Department of Radiology, MR Centre of Excellence, Medical University Vienna, Austria

*Breast Cancer Research* 2010, **12**(Suppl 3):O4 (doi: 10.1186/bcr2651)

**Purpose** To develop a 3.0 Tesla breast imaging protocol that combines high temporal and spatial resolution 3D MR sequences for quantitative time course and morphological analysis of breast lesions.

**Materials and methods** One hundred and sixty-five breast lesions classified by mammography or ultrasound as BIRADS 4 and 5 were included in this prospective IRB-approved study. The MRI protocol consisted of a coronal T2-weighted TIRM and a coronal combined high temporal and spatial resolution T1-weighted sequence before and after application of a standard-dose Gd-DOTA (VIBE with a high temporal resolution of SI 1.7 mm isotropic; TA 3.45 min for 17 measurements; FLASH with high spatial resolution of SI 1 mm isotropic; TA 2 min). Lesion size and morphology were assessed according to the BIRADS classification. ROIs for suspicious areas were manually drawn and evaluated for contrast-enhancement behavior by plotting intensity courses against time. Sensitivity and specificity with a 95% confidence interval and the negative predictive value (NPV) and positive predictive value (PPV) were calculated. Diagnostic accuracy was assessed. The histopathological diagnoses were used as the standard of reference.

**Results** All malignant breast lesions were identified correctly with a sensitivity of 100%, a specificity of 84% and a diagnostic accuracy of 95.7%. PPV was 0.94 and a NPV 1. All seven false positive lesions were lesions with atypia.

**Conclusions** The proposed combined 3 Tesla MR imaging protocol, comprising both high temporal and spatial resolution, enabled an accurate detection and assessment of breast lesions with high sensitivity and specificity reducing false positive breast biopsies

#### O5

##### MR visible only lesions: what are the predictors for malignant outcome?

M Bhattacharyya, F Ng, W Teh  
Northwick Park Hospital, Harrow, UK

*Breast Cancer Research* 2010, **12**(Suppl 3):O5 (doi: 10.1186/bcr2652)

**Introduction** To correlate pathological outcomes of MRI vacuum biopsies on MRI visible only breast lesions with lesion morphology, time-enhancement curves and clinical indications to determine the use of these as predictors for malignancy.

**Methods** A retrospective analysis of 277 patients referred for MRI-guided vacuum biopsies of impalpable breast lesions visible only on MRI was performed. All patients had a minimum follow-up period of 11 months. MRI biopsies were undertaken on a 1.5 T magnet using a minimum of 12 passes of vacuum-assisted biopsies. The pathological findings were correlated against BI-RADS appearances and time-enhancement characteristic of the lesions and against the clinical indications for MRI examination.

**Results** A total of 286 vacuum biopsies were undertaken. Eighty-one were malignant (28.3%), of which 72.8% are masses and 27.2% are nonmasses. Only two malignant lesions had a type 1 curve (2.5%), compared with malignant lesions with type 2 (54.3%) and type 3 curves (43.2%). Both malignant lesions with type 1 curve had a suspicious morphology. Nonmalignant lesions with type 3 enhancement included lymph nodes, fibroadenomatoid hyperplasia, papillary lesions, fibrocystic change and lobular neoplasia.

**Conclusions** Lesion morphology and time-enhancement curves are useful predictors of malignancy and can be used to develop an algorithm to help direct appropriate biopsy of MRI-detected lesions. We recommend that in the absence of suspicious morphology, only lesions with type 2 and type 3 curves should be subjected to MRI-guided biopsy.

#### O6

##### Comparison of film screen, computed radiography and direct digital mammography in the Southern Derby screening programme

M Bagnall, AE Turnbull, S Puri

Breast Unit, Royal Derby Hospital, Derby, UK

*Breast Cancer Research* 2010, **12**(Suppl 3):O6 (doi: 10.1186/bcr2653)

**Introduction** Our screening programme has been fully digital since April 2009 and utilises a combination of computed radiography (CR) (Fuji Profect) and three direct digital mammography (DDM) mammographic systems (Fuji Amulet, GE DS and GE Essential). This study compares the performance of our CR and DDM systems against film screen (FS) mammography in a real-life screening environment.

**Methods** Southern Derbyshire screening episodes between April 2007 and April 2010 were interrogated on NBSS using a Crystal report. Recall and cancer detection rates were collected according to mammography type. Data were analysed for significance using the chi-squared test.

**Results** A total of 66,989 screening episodes were recorded, 22,039 FS (recall rate 3.23%, cancer detection 8.08/1,000), 30,739 CR (recall rate 2.73%, cancer detection 7.87/1,000) and 14,157 DDM (recall rate 3.87%, cancer detection 9.89/1,000). Recall rates compared with FS were statistically significantly different for CR ( $P = 0.0007$ ) and DDM ( $P = 0.0016$ ). Cancer detection rates compared with FS mammography were not significantly different for either CR ( $P = 0.833$ ) or DDM ( $P = 0.081$ ), although there was a significant difference found between CR and DDM ( $P = 0.035$ ).

**Conclusions** DDM in our programme has detected an increased number of cancers but at an increased recall rate. CR has detected a similar number of cancers as FS mammography at a lower recall rate and the study supports the use of CR in our programme. As an interim measure in changing to a fully DDM service it has allowed us to spread costs whilst adopting a single digital workflow, which is efficient and safe for our clients.

## POSTER PRESENTATIONS

#### P1

##### Breast density as a predictor of breast cancer risk

G Lip<sup>1</sup>, N Zakharova<sup>2</sup>, SW Duffy<sup>2</sup>, MGC Gillan<sup>1</sup>, FJ Gilbert<sup>1</sup>

<sup>1</sup>University of Aberdeen, UK; <sup>2</sup>Queen Mary University of London, UK

*Breast Cancer Research* 2010, **12**(Suppl 3):P1 (doi: 10.1186/bcr2654)

**Introduction** As a part of a retrospective study of computer-aided detection in breast cancer screening, we recorded the percentage of the breast density on a visual analogue scale on 4,866 routine screening mammograms taken in 1996 as part of the North East of Scotland Breast Screening Service. In these women, 284 breast cancers were diagnosed from the time of the original mammograms up until February 2010.

**Methods** The main goal was to evaluate breast density as a breast cancer risk factor by detection mode, histology and time since the original mammogram. The association of density with risk of breast cancer was assessed using logistic regression giving odds ratios per 10% increase in density, and by comparison of continuous mean densities between particular groups of cancers and those who did not develop breast cancer.

**Results** After adjusting for age, breast density was significantly associated with cancer in the first 6 years after the original mammogram (OR per 10% density = 1.08, 95% CI = 1.01 to 1.15,  $P = 0.03$ ), but not with cancer more than 6 years after the mammogram (OR = 1.01, 95% CI = 0.93 to 1.10,  $P = 0.8$ ). There was a statistically significant association between histological type of tumour and breast density ( $P = 0.02$ ). The mean densities for no cancer, invasive ductal carcinoma, DCIS and invasive lobular carcinoma were 32% (SD 23%), 33% (21%), 35% (26%) and 44% (24%), respectively. The effect of density on risk varied significantly by detection mode ( $P = 0.02$ ), with highest densities being observed in interval cancers arising more than 1 year after the mammogram (55% compared with 32% in those with no cancer).

**Conclusions** Breast density as measured by visual analogue assessment is strongly associated with late interval cancers and with lobular carcinoma. Its predictive value for risk, however, declines with time since its measurement.

**P2**

**Flat epithelial atypia: biological significance on core biopsy**

S Rajan, A Shaaban, B Dall, N Sharma  
 Leeds Teaching Hospitals NHS Trust, Leeds, UK  
*Breast Cancer Research* 2010, **12(Suppl 3)**:P2 (doi: 10.1186/bcr2655)

**Introduction** Flat epithelial atypia (FEA) is seen with increasing frequency following biopsy of calcification detected through screening. FEA is often associated with more significant lesions including atypical ductal hyperplasia and ductal carcinoma *in situ* (DCIS). It is postulated that FEA may even represent the earliest morphological manifestation of DCIS and a precursor to invasive carcinoma. However, the significance of pure FEA still remains unclear. We aim to review the radiological and pathological features of FEA and evaluate the significance of FEA on needle core biopsy.

**Methods** We performed a retrospective analysis of all needle core biopsies containing FEA in the pathology database from April 2008 to April 2010. For each case the following data were recorded: mammographic features, method of further sampling (mammotome or diagnostic surgical biopsy) and histology from needle core biopsy, mammotome biopsy and surgical biopsy.

**Results** There were 35 needle core biopsies that contained pure FEA, of which 89% (31/35) were associated with mammographic calcification. Following initial core biopsy, 21 patients had further sampling with mammotome biopsy, 13 patients underwent diagnostic surgical biopsy and one patient was not suitable for further intervention. There was an upgrade to DCIS in 18% (6/34) and invasive carcinoma in 3% (1/34).

**Conclusions** Pure FEA on core biopsy is upgraded to carcinoma in 21% (7/34) of cases on further sampling and it is vital that we do not underestimate the biological significance of FEA. Increasing the awareness of FEA is crucial to ensure consistent and appropriate patient management.

**P3**

**Two-view 2D digital mammography versus one-view digital breast tomosynthesis**

MJ Mitchell, RK Wasan, A Iqbal, C Peacock, DR Evans, JC Morel  
 King's College Hospital, London, UK  
*Breast Cancer Research* 2010, **12(Suppl 3)**:P3 (doi: 10.1186/bcr2656)

**Introduction** In routine breast screening using 2D digital mammography (2DM), mediolateral-oblique (MLO) and craniocaudal (CC) views are performed to maximise cancer detection. Digital breast tomosynthesis (DBT) improves the visibility of lesions by eliminating the problem of superimposition of normal structures, and there is uncertainty regarding the need for two views. The purpose of this study is to compare the accuracy of two-view 2DM with one-view DBT.

**Methods** Five hundred and one cases were evaluated from the DBT trial dataset of clients recalled for further workup after their initial film-screen mammography. Bilateral two-view 2DM and DBT examination were performed in all study subjects. Mammography scores (1 to 5) based on RCR Breast Group criteria were recorded and an overall score for 2DM was established based on the highest value of MLO and CC scores. Unblinded interpretation of the 2DM followed by MLO-alone DBT was carried out. Statistical analysis was done using the receiver-operative characteristic (ROC).

**Results** There were 111 (22.1%) cancers. The ROC area under the curve (AUC) for two views combined 2DM was 0.915 and for MLO-alone DBT was

0.960 (difference 0.045;  $P = 0.009$ ). The distribution of M-scores against the histology-proven malignant lesions is presented in Table 1.

**Conclusions** In this series, one-view (MLO-alone) DBT had superior sensitivity compared with two-view 2DM.

**P4**

**Accuracy of breast cancer detection with full-field digital mammography and integral computer-aided detection correlated with breast density as assessed by a new automated volumetric breast density measurement system**

K Pinker<sup>1,2</sup>, N Perry<sup>2</sup>, S Milner<sup>2</sup>, K Mokbel<sup>2</sup>, S Duffy<sup>3</sup>  
<sup>1</sup>Department of Radiology, Division of Molecular and Gender Imaging, Medical University Vienna, Austria; <sup>2</sup>Princess Grace Hospital, The London Breast Institute, London, UK; <sup>3</sup>Wolfson Institute, Queen Mary College, University of London, UK  
*Breast Cancer Research* 2010, **12(Suppl 3)**:P4 (doi: 10.1186/bcr2657)

**Purpose** To assess the diagnostic performance of computer-aided detection (CAD) for full-field digital mammography (FFDM) correlated with breast density assessed by an automated breast density measurement system (Hologic, Quantra) in breast cancers and age-matched healthy controls.

**Materials and methods** Two hundred breast cancers imaged with FFDM and 200 age-matched healthy controls were evaluated retrospectively using CAD. A CAD mark was scored true-positive if it correctly indicated a malignant lesion. All other CAD marks were considered false. CAD sensitivity and specificity were calculated and correlated with mammographic breast density (%).

**Results** CAD correctly identified 157 of the 200 cancers, a sensitivity of 79%. Sensitivity was suggestively but nonsignificantly lower with increased density ( $P = 0.09$ ). In those cancer cases with density at or below the median of 20%, sensitivity was 82%, compared with 75% in those with density above the median. The presence of one or more false CAD prompts was suggestively but not significantly more likely in controls than cases (87% vs. 80%,  $P = 0.06$ ). The number of false prompts was significantly higher in controls (average 3.6 vs. 2.6,  $P < 0.001$ ). False prompts were significantly less likely with higher density ( $P = 0.008$ ). False prompts were present in 86% of cases and controls with density at or below the median, and in 81% of those with density above the median.

**Conclusions** Increased breast density is significantly associated with higher specificity of CAD, and there is suggestive evidence that it is also associated with lower sensitivity.

**P5**

**Surveillance following breast cancer: is it cost-effective?**

L Tennent<sup>1,2</sup>, G MacLennan<sup>1</sup>, SD Heys<sup>3,4</sup>, F Gilbert<sup>4,5</sup>, L Vale<sup>1,2</sup>, Mammographic Surveillance HTA Group  
<sup>1</sup>Health Services Research Unit, University of Aberdeen, UK; <sup>2</sup>Health Economics Research Unit, University of Aberdeen, UK; <sup>3</sup>Division of Applied Medicine, School of Medicine and Dentistry, University of Aberdeen, UK; <sup>4</sup>Aberdeen Royal Infirmary, NHS Grampian, Aberdeen, UK; <sup>5</sup>Aberdeen Biomedical Imaging Centre, University of Aberdeen, UK  
*Breast Cancer Research* 2010, **12(Suppl 3)**:P5 (doi: 10.1186/bcr2658)

**Introduction** There is debate about the role and optimal organisation of follow-up following treatment for primary breast cancer. We estimated using the best available evidence whether early detection by surveillance of ipsilateral breast tumour recurrence (IBTR) and metachronous contralateral breast cancer (MCBC) was cost-effective.

**Methods** An economic model compared alternative surveillance strategies involving mammographic surveillance and/or clinical follow-up performed at differing surveillance intervals. The model structure was based upon discussions with the clinical experts involved in the study, a survey of UK breast surgeons and radiologists, and the literature. Data to populate the model came from a series of systematic reviews and an analysis of the West Midlands Cancer Intelligence Unit Breast Cancer Registry. Results of the model were presented as incremental cost per QALYs – a measure of relative efficiency.

**Results** The surveillance strategy most likely to be cost-effective was mammographic surveillance alone provided every 12 to 24 months. This result held for women who had previously received either breast-conserving surgery or mastectomy. Results were sensitive to primary tumour characteristics (size,

**Table 1 (abstract P3)**

Imaging score	MLO-CC combined 2DM, n (%)	MLO-alone DBT, n (%)	Percentage difference, Δ
M1	1	0	0
M2	0	0	0
M3	28 (25.2%)	18 (16.2%)	↓9%
M4	32 (28.8%)	26 (23.4%)	↓5.4%
M5	50 (45.0%)	67 (60.3%)	↑15.3%

grade, nodal involvement) used to define the likelihoods of developing an IBTR or MCBC. More intensive follow-up of women with higher likelihood of developing IBTR or MCBC may be worthwhile.

**Conclusions** Our conclusions remain tentative due to the paucity of the underlying evidence base but suggest surveillance is likely to improve survival, with a strategy of mammography alone every 12 to 24 months appearing cost-effective.

#### P6

##### **A pilot study to evaluate assisted freehand ultrasound elasticity imaging in the sizing of early breast cancer: a comparison of B-mode and assisted freehand ultrasound elasticity ultrasound with histopathology measurements**

R English<sup>1</sup>, J Li<sup>2</sup>, A Parker<sup>1</sup>, D Roskell<sup>1</sup>, RF Adams<sup>1</sup>, V Parulekar<sup>1</sup>, J Baldwin<sup>1</sup>, Y Chi<sup>2</sup>, A Noble<sup>2</sup>

<sup>1</sup>Oxford Radcliffe Hospitals NHS Trust, Oxford, UK; <sup>2</sup>University of Oxford, UK  
*Breast Cancer Research* 2010, 12(Suppl 3):P6 (doi: 10.1186/bcr2659)

**Purpose** Preoperative breast cancer sizing is required for surgical planning. Breast ultrasound is widely used but may not be accurate. Assisted freehand ultrasound (AFUSON) of the breast is a novel method of ultrasound scanning, combining semi-automated elasticity ultrasound with B-mode imaging. This pilot study investigates whether AFUSON sizing corresponds more closely with wide local excision tumour dimensions than with B-mode alone.

**Methods** Twenty-three patients with early breast cancer were recruited with ethical approval through the NHSBSP. B-mode ultrasound and AFUSON images were acquired in predefined planes. Pathology slices were taken in the corresponding longitudinal plane and were digitally scanned. Assessment of tumour dimensions, area and contour were made on B-mode, AFUSON and histopathology scans. The findings were correlated.

**Results** Although there were significant limitations in this pilot study, the tumour dimension accuracy increased from 66% (B-mode alone) to 82% (AFUSON). Tumour area accuracy increased from 61% (B-mode alone) to 90% (AFUSON). Some AFUSON contour images showed a high visual correlation with the equivalent histopathology scans.

**Conclusions** This pilot study suggests that AFUSON may be useful in early breast cancer sizing. Further studies will be done to acquire more data and to address some of the shortfalls in the study.

#### P7

##### **Promoting early symptomatic presentation in older women with breast cancer in the NHS breast screening programme**

LJL Forbes<sup>1</sup>, L Atkins<sup>1</sup>, S Sellars<sup>2</sup>, J Patnick<sup>2</sup>, L Tucker<sup>1</sup>, AJ Ramirez<sup>1</sup>

<sup>1</sup>King's College London, London, UK; <sup>2</sup>NHS Screening Programmes, Sheffield, UK  
*Breast Cancer Research* 2010, 12(Suppl 3):P7 (doi: 10.1186/bcr2660)

**Introduction** Women over 70 have poorer breast cancer survival than younger women, and this may be due to late stage at presentation [1]. Promoting early presentation with symptoms in older women attending for their final round of breast screening may reduce stage at diagnosis cost-effectively, and is unlikely to lead to overdiagnosis. We tested the efficacy of the 10-minute radiographer-delivered Promoting Early Presentation (PEP) Intervention to promote early presentation by increasing breast cancer awareness in the NHS Breast Screening Programme.

**Methods** We randomised 867 women attending their final round of screening to receive the PEP Intervention or usual care, measuring breast cancer awareness at baseline and 1 year. We systematically reviewed the evidence of effectiveness of interventions to promote cancer awareness and early presentation.

**Results** At 1 year, the intervention increased the proportion breast cancer aware compared with usual care (24% vs. 4%; odds ratio = 15.2, 95% CI = 4.8 to 47.8). The systematic review found one randomised trial of a one-to-one intervention that showed a much smaller effect on breast cancer awareness.

**Conclusions** The PEP Intervention is more effective than any other intervention to promote breast cancer awareness. It will now be offered to all women attending for a final mammogram in three NHS breast screening services, to assess costs and feasibility and to measure its effect on breast cancer awareness in routine clinical practice. If implemented across the whole Programme, the PEP Intervention has the potential to reduce avoidable deaths from delayed symptomatic presentation in older women.

#### Reference

1. Moller H, Sandin F, Bray F, Klint A, Linklater KM, Purushotham A, Robinson D, Holmberg L: **Breast cancer survival in England, Norway and Sweden: a population-based comparison.** *Int J Cancer* 2010, 127:2630-2638.

#### P8

##### **Mammographic follow-up of patients after treatment for breast cancer: is 5 years enough?**

D Vaile<sup>1</sup>, LB Williams<sup>1</sup>, AC Borley<sup>2</sup>, PJ Barrett-Lee<sup>2</sup>, P Young<sup>3</sup>

<sup>1</sup>Velindre Cancer Centre, Cardiff, UK; <sup>2</sup>Velindre Cancer Centre, Cardiff, UK; <sup>3</sup>University Hospital of Wales, Cardiff, UK

*Breast Cancer Research* 2010, 12(Suppl 3):P8 (doi: 10.1186/bcr2661)

**Introduction** Velindre Cancer Centre (VCC), Cardiff provides radiotherapy and oncology services to the population of 1.5 million across southeast Wales. Historically at Velindre, breast cancer patients are followed up for at least 10 years, with annual mammography underpinning the service. The optimal length for continued annual surveillance has been debated and reduction to 5 years follow-up suggested. Therefore, a retrospective audit of breast cancers diagnosed on follow-up mammograms was undertaken to support the proposed reduced length of mammographic follow-up.

**Methods** Using the RIS and HIS electronic databases, follow-up mammograms over a 3-year period from 1 June 2006 to 31 May 2009 were collected and their report codes checked. All mammogram reports are coded using the Breast Imaging Reporting and Data System (BI-RADS). All mammograms coded 3 and above were identified. Subsequent radiological and histological reports were reviewed to identify confirmed malignancies.

**Results** In this 3-year period, there were 6,294 follow-up mammogram examinations at VCC. Ninety-seven reports were coded 3 or above (1.5%). Fifty-six new malignancies were confirmed. Of these, 44 (79%) occurred more than 5 years from original diagnosis.

**Conclusions** The results do not support reducing the length of follow-up to 5 years. Further analysis of original pathology will be undertaken to attempt to risk-stratify patients and thus allow tailored follow-up regimes to be developed.

#### P9

##### **An investigation of workstation image manipulation usage when examining FFDM images**

Y Chen<sup>1</sup>, J James<sup>2</sup>, A Evans<sup>3</sup>, A Turnbull<sup>4</sup>, A Gale<sup>1</sup>

<sup>1</sup>Loughborough University, Loughborough, UK; <sup>2</sup>Nottingham Breast Institute, Nottingham, UK; <sup>3</sup>University of Dundee, UK; <sup>4</sup>Derby Breast Unit, Derby, UK

*Breast Cancer Research* 2010, 12(Suppl 3):P9 (doi: 10.1186/bcr2662)

**Introduction** With the introduction of digital breast screening across the UK, screeners need to learn how best to inspect these images. A key advantage over mammographic film is the facility to use workstation image manipulation tools.

**Methods** Forty two-view FFDM screening cases, representing malignant, normal and benign appearances, were examined by 14 radiologists and advanced practitioners from two UK screening centres. For half the cases, the mammography workstation image manipulation tools could be employed; and for the other half these were not used. Participants classified each case and indicated whether an abnormality was present. Throughout the study, the participants visual search behaviour as well as their image manipulations were recorded.

**Results** Whether or not image manipulation tools were used made very little difference to overall performance (*t* test, *P* > 0.05) as confirmed by JAFROC analysis figure-of-merit values of 0.816 and 0.838 (with and without tools, respectively); performance not using tools was better. However, using tools significantly increased inspection time (*P* < 0.5) as well as participants' confidence. Detailed examination of participants' image inspection behaviour elicited that when imaging tools were used then they spent 17 to 77% of their time manipulating the images; with the less experienced participants spending more time using such tools. Eye movement data demonstrated that when abnormalities were missed then this was typically due to search errors.

**Conclusions** For these cases, whilst using imaging tools was not necessary to identify abnormalities, their use improved confidence, especially in identifying normal appearances. With experience, less use of such tools was evident.

### P10

#### Preliminary assessment of ShearWave™ elastography features in predicting breast lesion malignancy

DO Cosgrove<sup>1</sup>, C Doré<sup>2</sup>, C Tourasse<sup>2</sup>, R Ohlinger<sup>3</sup>, H Madjar<sup>4</sup>, R Hooley<sup>5</sup>, C Balu-Maestro<sup>6</sup>, E Mendelson<sup>7</sup>, W Svensson<sup>1,8</sup>, A Tardivon<sup>9</sup>, A Cossi<sup>10</sup>, L Barke<sup>10,11</sup>, L Larsen<sup>10,12</sup>

<sup>1</sup>Imperial College, Hammersmith Hospital, London, UK; <sup>2</sup>Jean Mermoz Private Hospital, Lyon, France; <sup>3</sup>University Hospital, Frauenklinik, Greifswald, Germany; <sup>4</sup>German Diagnostic Clinic, Wiesbaden, Germany; <sup>5</sup>Yale Medical Center, New Haven, CT, USA; <sup>6</sup>Centre Antoine Lacassagne, Nice, France; <sup>7</sup>Northwestern Memorial Hospital, Chicago, IL, USA; <sup>8</sup>Charing Cross Hospital, London, UK; <sup>9</sup>Centre Antoine Lacassagne, Nice, France; <sup>10</sup>Institut Curie, Paris, France; <sup>11</sup>Sally Jobe Breast Center, Denver, CO, USA; <sup>12</sup>University of Southern California, Los Angeles, CA, USA  
*Breast Cancer Research* 2010, **12**(Suppl 3):P10 (doi: 10.1186/bcr2663)

**Introduction** ShearWave™ elastography (SWE) provides a quantitative measurement of tissue stiffness with high spatial resolution and may improve characterization of breast masses. The goal of this study was to evaluate the reproducibility of SWE and the impact of adding SWE features to the BI-RADS classification of breast masses from the first 1,000 cases in a prospective multicenter trial.

**Methods** SWE studies were performed on a prototype of the Aixplorer system (Supersonic Imagine, Aix-en-Provence, France). A subset of 192 breast lesions (42.71% malignant) was analyzed. Reproducibility of SWE images and measurements was assessed; logistic regression analysis was performed to predict the pathology findings. SWE features were added to the ultrasound BI-RADS to generate models that were challenged by comparing the areas under the ROC curves (Az), and the sensitivity and specificity scores.

**Results** In the preliminary analysis, intra-operator reproducibility of SWE size ( $R \geq 0.93$ ) and mean elasticity ( $R = 0.88$ ) measurements were in near-perfect agreement. Using the best three-variable model (BIRADS + elasticity shape + maximum elasticity), the Az increased from 0.77 to 0.93 and specificity increased from 61.8% to 87.3%, although sensitivity decreased from 92.7% to 87.8%. Adding more variables did not effect further improvements.

**Conclusions** In this ongoing study, SWE provided reproducible information (elasticity values and SWE mapping) that improved the characterization of breast lesions. These features are directly linked to the characteristics of SWE: local quantification and millimeter resolution. Further evaluation of the study is in progress.

### P11

#### To recognise the imaging of complications from Macrolane™ injection

SE McWilliams<sup>1</sup>, L Wilding<sup>2</sup>

<sup>1</sup>Guy's and St Thomas' NHS Trust, London, UK; <sup>2</sup>West Middlesex University Hospital, London, UK

*Breast Cancer Research* 2010, **12**(Suppl 3):P11 (doi: 10.1186/bcr2664)

**Introduction** Macrolane™ volume restoration factor (VRF) (Q-Med) is in vogue for use in breast augmentation. There is sparse literature on the imaging characteristics of complications resulting from Macrolane™ injection.

**Methods** This study describes the multimodality imaging of 12 patients from three centres who had breast complications as a result of Macrolane™ injection. The patients had all undergone Macrolane™ injection at varying intervals prior to presentation. Macrolane™ consists of non-animal stabilised hyaluronic acid (NASHA™) and is approved for nonsurgical breast augmentation. Treatment involves injection of up to 100 ml fluid, superficial to the pectoral muscle and deep to the glandular breast disc, and is semi-permanent, usually only lasting up to 1 year before a top-up injection is required.

**Results** Presenting symptoms included breast lumps, breast pain and axillary pain. The complications seen on imaging included abscess formation, indeterminate masses, subpectoral collections and complex cystic collections. The fluid and indeterminate masses were not all resorbed in the timeframe expected of Macrolane™ and remained *in situ* in some cases for at least 2 years.

**Conclusions** Macrolane™ injection is associated with long-term complications and creates diagnostic challenges on breast imaging that are only beginning to emerge in the breast clinics and that may warrant triple assessment.

### P12

#### Texture analysis applied to full-field digital mammography: ability to discriminate between invasive ductal and invasive lobular breast cancer – preliminary results

M Mayerhoefer<sup>1</sup>, N Perry<sup>2</sup>, S Milner<sup>2</sup>, K Mokbel<sup>2</sup>, S Duffy<sup>3</sup>, K Pinker<sup>1,2</sup>

<sup>1</sup>Department of Radiology, Division of Molecular and Gender Imaging, Medical University Vienna, Austria; <sup>2</sup>Princess Grace Hospital, The London Breast Institute, London, UK; <sup>3</sup>Wolfson Institute, Queen Mary College, University of London, UK  
*Breast Cancer Research* 2010, **12**(Suppl 3):P12 (doi: 10.1186/bcr2665)

**Purpose** To determine texture features of IDC and invasive lobular carcinoma (ILC) of the breast on full-field digital mammography (FFDM). To evaluate the ability of texture analysis to differentiate between those tumor types.

**Materials and methods** Fourteen IDC and nine ILC imaged with FFDM were included in this study. For each lesion the ROI was manually defined covering the lesion and 1 cm normal-appearing breast tissue around the lesion. Texture features derived from the grey-level histogram, the co-occurrence matrix, the run-length matrix, the absolute gradient, the autoregressive model, and the wavelet transform were calculated for the ROIs. Fisher coefficients were calculated to determine which texture features were best-suited for distinguishing between IDC and ILC. Based on the combination of those five texture features with the highest Fisher coefficients, lesion classification was performed, using linear discriminant analysis (LDA) and principal component analysis (PCA) classifiers, as well as a *k*-means clustering algorithm. Classification accuracy was used as the primary outcome measure.

**Results** Of the five texture features with the highest Fisher coefficients, the top four were derived from the wavelet transform. Using LDA and PCA, classification accuracies of 82.6% (19 of 23 lesions) and 78.3% (18 of 23 lesions) were achieved, respectively. *k*-means clustering also yielded a similar classification accuracy of 82.6% (19 of 23 lesions).

**Conclusions** Texture features, best suited for discrimination between ILC and IDC, are derived from the wavelet transform. Texture analysis of breast cancer cases imaged with FFDM allows a good degree of accuracy of discrimination between IDC and ILC.

### P13

#### Sensitivity of integral computer-aided detection with full-field digital mammography for detection of breast cancer according to different histopathological tumor types and appearances

K Pinker<sup>1,2</sup>, N Perry<sup>2</sup>, S Milner<sup>2</sup>, K Mokbel<sup>2</sup>, S Duffy<sup>3</sup>

<sup>1</sup>Department of Radiology, Division of Molecular and Gender Imaging, Medical University Vienna, Austria; <sup>2</sup>Princess Grace Hospital, The London Breast Institute, London, UK; <sup>3</sup>Wolfson Institute, Queen Mary College, University of London, UK  
*Breast Cancer Research* 2010, **12**(Suppl 3):P13 (doi: 10.1186/bcr2666)

**Purpose** To retrospectively evaluate the sensitivity of computer-aided detection (CAD) for full-field digital mammography (FFDM) in 360 breast cancers with regard to mammographic appearance and histopathological tumor type.

**Materials and methods** Three hundred and sixty breast cancers imaged with FFDM were evaluated retrospectively using CAD. A CAD mark was scored true positive (TP) if it correctly indicated a malignant lesion. All other CAD marks were considered false. Cancer cases were classified as microcalcifications (64), masses (196), or both (100). Histopathological findings were classified as IDC, ILC, DCIS or other. Sensitivity values for CAD according to mammographic appearance and, histopathological findings were analyzed using chi-squared tests.

**Results** A TP mark was observed on 319 out of the 360 cancers (89%). Calcifications were significantly ( $P < 0.001$ ) more likely to be marked than masses, 163/164 (99%) compared with 244/296 (82%). The probability of a mass TP mark was significantly related to histological type ( $P < 0.001$ ), with sensitivity being greatest for IDC at 76% (167/221) compared with 67% (38/57) for ILC, 31% (16/51) for DCIS and 74% (23/31) for other types. The probability of a calcification TP mark was also significantly related to histological type, with sensitivity being greatest for DCIS at 75% (38/51), compared with 43% (96/221) for IDC, 33% (19/57) for ILC and 32% (10/31) for other types.

**Conclusions** CAD prompted the significant majority of radiological abnormalities related to cancers and was most accurate for detection of calcification and DCIS, less so for mass lesions and ILC.

**P14**

**Can touch imprint cytology replace fine needle aspiration within current clinical practice?**

H Kinkaid, J Yarr, SR Hall, G McCusker, M McStay, GM Briggs  
Southern Health and Social Care Trust, Portadown, UK  
*Breast Cancer Research* 2010, **12**(Suppl 3):P14 (doi: 10.1186/bcr2667)

**Introduction** To investigate whether touch imprint cytology (TIC) of needle core biopsy (NCB) is as effective as fine needle aspiration cytology (FNAC) for providing same-day diagnosis of benign and malignant breast lesions at our one-stop symptomatic breast clinic.

**Methods** We prospectively studied 426 women with image-detected breast lesions who underwent FNAC and NCB with subsequent TIC. All of the FNAC and TIC samples were sent for immediate reporting. These were read by one of five consultant cytopathologists. The TIC results were subsequently compared with the definitive histopathology from either the core biopsy or the final surgical specimen.

**Results** Complete data were present for all patients. TIC was compared with FNAC in providing an accurate and definitive same-day diagnosis in lesions graded C2 (benign) and C5 (malignant). For FNAC, C2 = 75/426 and C5 = 210/426 allowing 66.8% of women a definite same-day diagnosis. For TIC, C2 = 92/426 and C5 = 223/426 allowing 73.8% of women a definite same-day diagnosis. There were no false positive results.

**Conclusions** The accuracy of TIC is at least equivalent to FNAC when used as a stand-alone technique for definitive same-day diagnosis from a single biopsy. We therefore conclude that FNAC is no longer necessary, thus saving a second invasive procedure.

**P15**

**A novel threshold-independent computer-aided detection algorithm for breast MRI**

O Hatsiopoulou<sup>1</sup>, O Kubassova<sup>2</sup>, I Jolley<sup>1</sup>, C Ingram<sup>1</sup>  
<sup>1</sup>Sheffield Teaching Hospitals NHS Foundation Trust, Sheffield, UK; <sup>2</sup>Image Analysis Ltd, Leeds, UK  
*Breast Cancer Research* 2010, **12**(Suppl 3):P15 (doi: 10.1186/bcr2668)

**Introduction** Image degradation due to motion artefact in breast MRI represents a diagnostic challenge. Tumours are often detected manually by a radiologist or with computer-aided detection (CAD) systems, which utilise areas of enhancement that meet a predefined threshold. The aim of this study was to test a new threshold-independent CAD algorithm and to correlate its findings to the conventional manual analysis.

**Methods** CAD was tested on retrospectively acquired MRIs of 14 patients with pathologically proven carcinomas. CAD results were obtained in a fully automated manner and the expert was blinded to the CAD findings. Noise artefacts were eliminated with the patient motion reduction algorithm and suspicious tissues were delineated using a novel all-timepoint-based, threshold-independent parametric map approach. The algorithm evaluates the shape of the curve as a whole and uses the noise integral to the image to discriminate malignant from benign tissues.

**Results** All CAD-identified tumours and generated kinetic curves were comparable with those of the manual analysis. In particular, tumour conspicuity was enhanced in two cases where image degradation by motion artefacts made data interpretation challenging to conventional analysis. See Figure 1.

**Conclusions** CAD results were favourably viewed by experts and 100% correlated to conventional manual tumour detection. In particular, CAD

appears to increase tumour conspicuity in cases with motion artefacts. Prospective analysis is required to test this model further.

**P16**

**Educational abstract**

Educational abstract not submitted for online publication.  
*Breast Cancer Research* 2010, **12**(Suppl 3):P16 (doi: 10.1186/bcr2669)

**P17**

**Clinical value of hybrid imaging for staging breast cancer in a district general hospital**

FR Canavan, E Lloyd, D Jones, J Edwards, M Powell  
Wrexham Maelor Hospital, Wrexham, UK  
*Breast Cancer Research* 2010, **12**(Suppl 3):P17 (doi: 10.1186/bcr2670)

**Introduction** Hybrid imaging, integrating anatomical computed tomography (CT) with functional single-photon emission computed tomography (SPECT), has emerged as a powerful diagnostic tool in breast cancer imaging. This dual modality increases the specificity of skeletal scintigraphy in detecting bony metastases and achieves accurate sentinel lymph node mapping, directly influencing the surgical approach. For patients with high-grade breast cancer, hybrid SPECT/CT provides the opportunity for a 'one-stop shop' with important implications for patient care, cost-effectiveness and follow-up.

**Methods** We included 50 women with >15 mm grade 2 or grade 3 invasive breast cancer attending our imaging department over 6 months. Each underwent SPECT/CT imaging protocol using a 16-slice Phillips Precedence. A questionnaire assessed type/number of imaging visits and perceived anxiety levels. Change to patient management, radiation dose and estimated costs were also collected from the trust patient and imaging information systems and multidisciplinary notes, to assess overall value.

**Results** One-third of patients underwent significant change in medical or surgical management based on hybrid imaging. Overall, >90% of patients surveyed reported higher satisfaction following a 'one-stop' visit. Cost and total radiation dose of combined imaging were more favourable than for single visits.

**Conclusions** Whilst hybrid SPECT/CT in breast imaging remains in its infancy, its potential to add value for the clinician and patient is clear. The positive advantages for patient management and convenience/cost suggested in our pilot study suggest it is likely to influence future breast cancer management protocols.

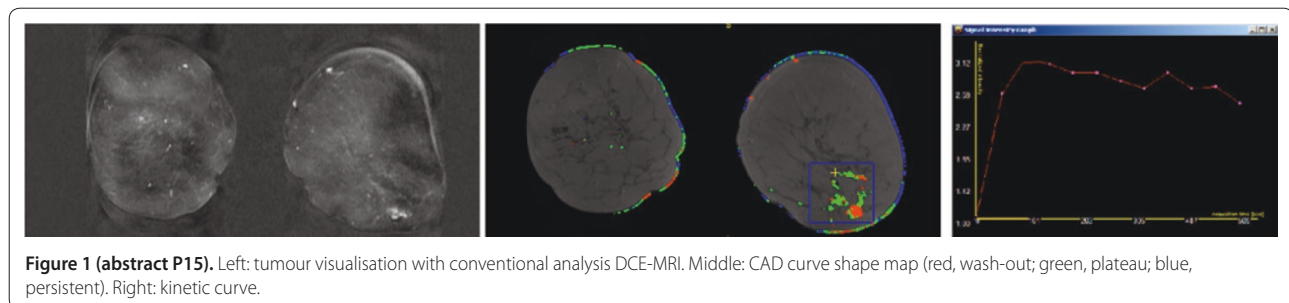
**P18**

**Comparison of 1.5T and 3T in assessment of suspicious breast lesions**

SK Arcot Ragupathy<sup>1</sup>, T Gagliardi<sup>1</sup>, TW Redpath<sup>2</sup>, S Flynn<sup>1</sup>, B Jagpal<sup>2</sup>, JKP Begley<sup>2</sup>, FJ Gilbert<sup>2</sup>  
<sup>1</sup>Aberdeen Royal Infirmary, Aberdeen, UK; <sup>2</sup>University of Aberdeen, UK  
*Breast Cancer Research* 2010, **12**(Suppl 3):P18 (doi: 10.1186/bcr2671)

**Introduction** MRI at 3T has advantages of increased spatial and temporal resolution but with known transmit field inhomogeneity problems. The objective of this study is to compare the confidence in characterising the breast lesions in 1.5T and 3T MRI examinations performed and to compare the conspicuity of the lesions.

**Materials and methods** Patients referred for a diagnostic MRI examination as part of their clinical work-up for a suspicious lesion or for preoperative



**Figure 1 (abstract P15).** Left: tumour visualisation with conventional analysis DCE-MRI. Middle: CAD curve shape map (red, wash-out; green, plateau; blue, persistent). Right: kinetic curve.

staging were recruited into this study following informed consent. The MRI was undertaken on a 1.5T GE CVi/NVi (Milwaukee, WI, USA) and a 3T Philips Achieva (Best, the Netherlands). T2W, dynamic T1W (voxel size 0.85 x 1.19 x 2 mm – 1.5 T MRI, and 0.6 x 0.6 x 2 mm – 3T MRI) and high-resolution fat-suppressed T1W postcontrast sequences (single-dose contrast) were carried out. The confidence level in morphology and contrast kinetics (three-point scale) and conspicuity for each lesion (five-point scale, -2 to +2) was assessed by a single observer (SKAR).

**Results** Seventeen patients were included in the study. Eleven patients had one or more lesions, giving 22 lesions. The confidence level in assessing morphology was high in 16/22 and 19/22 and in assessing contrast kinetics was high in 12/22 and 16/22 in 1.5T and 3T examinations, respectively. The mean and standard deviation of the conspicuity score are  $1.09 \pm 0.88$  for 3T. **Conclusions** The confidence in characterising and conspicuity of the breast lesions is improved and no lesions identified at 1.5T were missed at 3T MRI. 3T MRI can be used safely in clinical practice.

### P19 Effect of region of interest size in quantitative diffusion-weighted magnetic resonance imaging of the breast

N AlRashidi, T Gagliardi, T Ahearn, T Redpath, F Gilbert  
University of Aberdeen, UK

Breast Cancer Research 2010, 12(Suppl 3):P19 (doi: 10.1186/bcr2672)

**Introduction** In breast MRI, morphological and dynamic enhancement features determine whether a lesion is benign or malignant but specificity is low. Diffusion-weighted magnetic resonance imaging (DW-MRI) measures microscopic motion of water and gives quantitative measurement known as the apparent diffusion coefficient (ADC). This study was conducted to determine whether the whole of the lesion should be included within the region of interest (ROI) or whether a small ROI would differentiate benign from malignant disease.

**Methods** Fifteen female patients with 15 suspicious lesions were imaged on a 3T MRI machine (Philips HealthCare, Best, the Netherlands). DWI-MRI was performed with b-values of 0, 150, 800 s/mm<sup>2</sup> using single-shot SE-EPI (TR/TE = 9,543 ms/50 ms). The ROI of the lesion and of fibroglandular tissue was used to calculate ADC values. Histology or follow-up data were available for all lesions.

**Results** The mean ADC value of malignant lesions (13) from two small ROIs was  $0.954 \pm 0.145$  mm<sup>2</sup>/second and for benign (2) was  $1.69 \pm 0.17$  mm<sup>2</sup>/second (Figure 1a). The ADC values for the whole lesion were  $1.027 \pm 0.23$  mm<sup>2</sup>/second and  $1.78 \pm 0.293$  mm<sup>2</sup>/second, respectively (Figure 1b).

**Conclusions** There is a significant difference between ADC values from large and small ROIs ( $P < 0.05$ ), with small ROIs giving greater differentiation. DWI is a promising technique to improve specificity of breast MRI.

### P20 Negative predictive value for atypia and malignancy of 14-gauge core biopsy of breast papillomas

GT Mataka, MJ Pearson, AJ Maxwell

Royal Bolton Hospital, Bolton, UK

Breast Cancer Research 2010, 12(Suppl 3):P20 (doi: 10.1186/bcr2673)

**Introduction** Papillary lesions of the breast may be heterogeneous and associated with atypia or frank malignancy. Current practice is to perform wider sampling of lesions showing benign papilloma on core biopsy because of the risk of underestimation of disease. The literature, however, is unclear about the negative predictive value (NPV) of 14-gauge needle core biopsy for atypia or malignancy.

**Methods** A retrospective review of image-guided biopsies performed over an 11-year period from January 1999 to December 2009 was undertaken. We identified cases with a 14-gauge core biopsy diagnosis of benign papilloma. Patients with atypia or malignancy on core biopsy were excluded. The imaging features and number of core samples were documented. All patients subsequently underwent lesion excision.

**Results** Seventy-eight patients had a diagnosis of a benign papilloma on core biopsy. Subsequent excision was with vacuum-assisted biopsy in 48 and surgery in 30. Twenty-eight patients with microcalcification had a stereotactic-guided biopsy. Fifty patients with a mass had ultrasound-guided biopsy. Atypical ductal hyperplasia was found in three out of 28 (11%) who had microcalcification (mean number of 10 cores) and one out of 50 (2%) with a mass (mean number of three cores). Seventy-four (95%) patients had a benign papilloma only.

**Conclusions** The NPV for atypia and malignancy of 14-gauge core biopsy of papillomas is 95% in this series. Underestimation of disease is more common in lesions presenting with microcalcification. The current practice of wider sampling of all papillary lesions diagnosed on 14-gauge core biopsy should continue.

### P21 Educational abstract

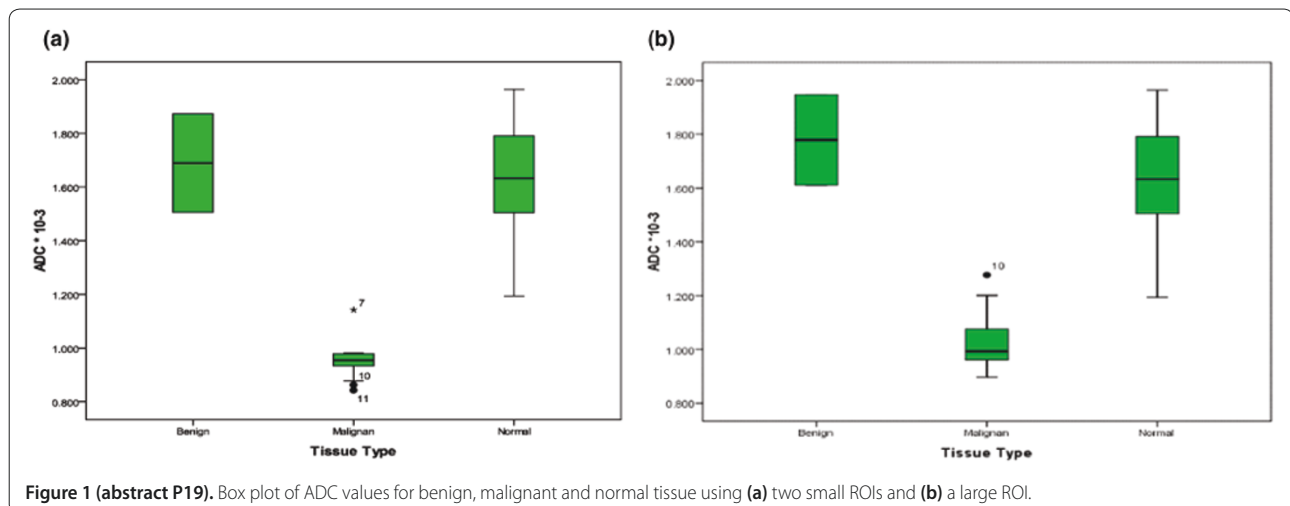
Educational abstract not submitted for online publication.

Breast Cancer Research 2010, 12(Suppl 3):P21 (doi: 10.1186/bcr2674)

### P22 Educational abstract

Educational abstract not submitted for online publication.

Breast Cancer Research 2010, 12(Suppl 3):P22 (doi: 10.1186/bcr2675)



**P23**

**Axillary lymph node fine needle aspiration in breast cancer staging: diagnostic impact of a second 20G spinal needle**

A Leaver<sup>1</sup>, M Cockburn<sup>1</sup>, J Gholkar<sup>1</sup>, CE Holmes<sup>1</sup>, N Sibal<sup>1</sup>, B Kaye<sup>1</sup>, L McLean<sup>1</sup>, V Wadehra<sup>2</sup>

<sup>1</sup>Royal Victoria Infirmary Breast Screening Unit, Newcastle-upon-Tyne, UK; <sup>2</sup>Royal Victoria Infirmary Cytology Department, Newcastle-upon-Tyne, UK

*Breast Cancer Research* 2010, **12**(Suppl 3):P23 (doi: 10.1186/bcr2676)

**Introduction** All breast cancer patients in our centre undergo ipsilateral axillary ultrasound, followed by fine needle aspiration (FNA) where appropriate in line with NICE guidelines. We use two needle passes into a suspicious node, without suction. Improved preoperative detection of nodal metastasis allows patients improved triage to appropriate axillary surgery. We present our analysis of the impact of the second needle in our axillary FNA procedure.

**Methods** All breast cancer patients undergoing axillary FNA from April 2010 to July 2010 were included, where possible. The first FNA was labelled '1' and the second '2'. Individual and overall FNA results were compared with final surgical pathology, where available.

**Results** The study included 27 female patients. There was a difference in the cytology grading (described LN0 to LN5) allocated between the first and second needle in five cases (19%). The second needle increased sample adequacy on three (11%) occasions. Of the 17 patients that had axillary surgery, three had no lymph node metastases and the preoperative FNA cytology was LN2. There were no false positive cytology results. Preoperative cytology was LN5 overall in 11/14 (79%) patients with nodal metastases, with LN5 obtained only in the second pass in 4/14 (29%) cases (first-pass results: LN2/LN2/LN0/LN0). No complications were reported.

**Conclusions** A second needle pass into suspicious axillary lymph nodes in breast cancer patients has been validated by this study, increasing our preoperative rate of detection of lymph node metastases.

**P24**

**Fine needle aspiration versus touch imprint cytology in ultrasound-guided core of breast masses**

A Leaver<sup>1</sup>, S Athey<sup>1</sup>, A O'Brien<sup>1</sup>, AJ Potterton<sup>1</sup>, A Redman<sup>1</sup>, L Lunt<sup>1</sup>, JD Hemming<sup>2</sup>

<sup>1</sup>Queen Elizabeth Hospital Breast Screening Unit, Gateshead, UK; <sup>2</sup>Queen Elizabeth Hospital Cytology Department, Gateshead, UK

*Breast Cancer Research* 2010, **12**(Suppl 3):P24 (doi: 10.1186/bcr2677)

**Introduction** The aim of this study was to compare the results of fine needle aspiration (FNAC, current practice) with imprint cytology (CIC) from ultrasound-guided cores taken in the one-stop clinic setting. CIC allows same-day results with one biopsy procedure. Literature suggests CIC provides a higher sensitivity/C5 rate, although there are few direct comparisons of CIC with FNAC.

**Methods** From October 2009 to April 2010, wherever possible, CIC was performed in patients undergoing both ultrasound-guided FNAC and core biopsy. CIC slides were independently reported blind to FNA results. Results were compared with core biopsy histology and therapeutic excision histology, when available.

**Results** The cases included 90 female patients with 93 masses (54 malignant, 39 benign masses based on final histology). In the malignant group the C5 rate was 61% (33/54) for FNAC, 83% (45/54) for CIC and 85% (46/54) for the combination of FNA and CIC. No cancers in this sample had an initially benign core result with malignant FNA or CIC result. In the benign group the C2 rate was 41% (16/39) for FNA, 69% (27/39) for CIC, and 64% (25/39) for the combination of FNA and CIC. There were no false positive C5 results. Imprints were easy to perform and there was no damage to the core biopsy material. Cytologists encountered no problems interpreting CIC.

**Conclusions** The use of CIC in ultrasound-guided core biopsies in place of conventional FNAC has been validated by this study. No significant obstacle to adopting core imprint cytology has been identified.

**P25**

**Educational abstract**

Educational abstract not submitted for online publication.

*Breast Cancer Research* 2010, **12**(Suppl 3):P25 (doi: 10.1186/bcr2678)

**P26**

**Educational abstract**

Educational abstract not submitted for online publication.

*Breast Cancer Research* 2010, **12**(Suppl 3):P26 (doi: 10.1186/bcr2679)

**P27**

**Effect of the introduction of preoperative MRI scans for lobular cancer in an individual breast unit**

H Cain, J Sinclair, A Martin, T Fasih, D Browell, K Clark, L Lunt, A Redman  
Queen Elizabeth Hospital, Gateshead, UK

*Breast Cancer Research* 2010, **12**(Suppl 3):P27 (doi: 10.1186/bcr2680)

**Introduction** NICE guidelines suggest that patients with lobular breast cancer should be offered an MRI scan to measure the tumour size and to exclude multifocality and contralateral tumours. The aim of this study was to ascertain the effect of this guideline.

**Methods** This guideline was introduced in January 2009. Patients with lobular cancer were selected from before and after this date. Cases were reviewed and compared for type of surgery, positive resection margins and alteration in patient management. The number of additional targeted USS and biopsies was also recorded.

**Results** Sixty-nine patients were included in the study, of which 22 had preoperative MRI scans. There was no significant difference in mastectomy rates (MRI = 45.5% vs. no MRI 57.5%,  $P = 0.44$ ) and no significant difference in positive margins following WLE (MRI 41% vs. no MRI 35%,  $P = 0.23$ ). Of the 22 MRIs 11 additional findings were reported, six in the contralateral breast, leading to nine targeted USS and eight further core biopsies. Three of these core biopsies confirmed malignancy. Two MRI scans demonstrated multifocality and one diagnosed contralateral DCIS. Four patients' management was altered due to the MRI result, one of these was due to an increase in size. There was one case of multifocality that was invisible on all imaging.

**Conclusions** This study has shown that the guideline for preoperative MRI scanning in lobular cancer will alter the surgical management in approximately 20% of patients. An additional 20% of patients will undergo additional imaging and biopsies that do not alter management.

**P28**

**Educational abstract**

Educational abstract not submitted for online publication.

*Breast Cancer Research* 2010, **12**(Suppl 3):P28 (doi: 10.1186/bcr2681)

**P29**

**An audit to assess the impact of introducing a protocol of bilateral whole breast and axillary ultrasound for assessment of screen-detected cancers**

IT Perera<sup>1</sup>, LS Wilkinson<sup>2</sup>

<sup>1</sup>Guy's and St Thomas' Hospitals NHS Trust, London, UK; <sup>2</sup>St George's Hospital, London, UK

*Breast Cancer Research* 2010, **12**(Suppl 3):P29 (doi: 10.1186/bcr2682)

**Introduction:** Our protocol for assessment of women with screen-detected malignancy was changed to include bilateral whole breast and axillary ultrasound (BBUS) following a prospective study that confirmed the benefit of this in 2002 [1]. This audit assesses the impact of introducing this change.

**Methods** Biopsy results for all women with screen-detected cancer diagnosed between April 2003 and March 2009 were reviewed to identify cases where multiple biopsies had been performed. The reason for additional biopsy and subsequent management were recorded. The data were compared with control data (2001) obtained prior to the introduction of the protocol, and with national outcome data for screen-detected cancer.

**Results** A total of 199,307 women were screened during the audit period, and 1,700 women were diagnosed with breast cancer. Table 1 demonstrates the findings for women diagnosed with cancer who had additional biopsies,



Table 1 (abstract P29)

	Audit (n = 1,700)	Control (n = 105)
Additional biopsy	318 (19%)	6 (5.7%)
Additional biopsy shows cancer	160 (9.4%)	6 (5.7%)
Contralateral biopsies	47 (2.8%)	0 (0%)
Bilateral cancer	22 (1.3%)	0 (0%)
FNAC of axillary node	150 (8.8%)	0 (0%)
FNAC shows nodal metastases	55 (3.2%)	0 (0%)

compared with the control population. Data for 2008/09 show that this unit has a repeat operation rate of 18% for non-invasive disease and 16% for invasive disease compared with national averages of 28% for non-invasive and 23% for invasive cancer [2].

**Conclusions** Additional cancers and axillary node metastases were detected as a result of introducing a policy of proactive assessment of disease extent. The unit has a favourable rate of re-operations compared with national data.

#### References

1. Wilkinson LS, Given-Wilson R, Hall T, Potts H, Sharma AK, Smith E: Increasing the diagnosis of multifocal primary breast cancer by the use of bilateral whole-breast ultrasound. *Clin Radiol* 2005, **60**:573-578.
2. National NHSBSP and ABS at BASO Breast Screening Audit 2008/9 report, West Midlands Cancer Intelligence Unit [http://www.wmpho.org.uk/wmciu/BQA9.htm]

#### P30

##### Does a second image-guided biopsy contribute to the management of B3 lesions?

JK Juttla<sup>1</sup>, W Teh<sup>2</sup>

<sup>1</sup>North London Breast Screening Service, Edgware, UK; <sup>2</sup>Northwick Park Hospital, Harrow, UK

*Breast Cancer Research* 2010, **12**(Suppl 3):P30 (doi: 10.1186/bcr2683)

**Introduction** B3 (benign with uncertain malignant potential) lesions such as atypias and papillary lesions have final surgical outcome of malignancy in about 20% of vacuum-assisted and 45% of image-guided core biopsies. We examine the benefits of undertaking a second image-guided biopsy in these cases.

**Methods** A retrospective study of all B3 lesions diagnosed between January 2008 and December 2009 at the North London Breast Screening Service.

**Results** Out of 235 biopsies in 167 women over a 2-year period, there were 191 B3 outcomes of which 59 had a final malignant outcome (30.8%). Following MDT discussion, 60/191 B3 lesions were subjected to a second biopsy (25.5%) and one lesion a third biopsy. These yielded a malignant diagnosis in 11 (18.3%) cases. Lesions successfully upgraded to malignancy included three microcalcification (MCC), three masses, three masses with MCC and one cyst with solid elements. Cancers diagnosed on second biopsies were one invasive ductal, one invasive papillary carcinoma and nine ductal carcinoma *in situ* (DCIS). All second biopsies were performed using a vacuum device with the initial biopsy method being 14G core biopsy in eight cases and vacuum-assisted in three cases. Second biopsies were therefore equally useful in upgrading MCC and masses and especially useful for DCIS.

**Conclusions** Second-time image-guided biopsies can successfully yield a definitive malignant diagnosis in B3 lesions (18.3%) and thus enable therapeutic rather than diagnostic surgery to be undertaken. Second biopsies are equally useful in the management of MCC, masses and masses with MCC.

#### P31

##### Educational abstract

Educational abstract not submitted for online publication.

*Breast Cancer Research* 2010, **12**(Suppl 3):P31 (doi: 10.1186/bcr2684)

#### P32

##### Screening MRI in patients at high risk of breast carcinoma from the Manchester family history clinic: our initial 2-year experience

Y Lim, E Hurley, P Riley

University Hospital of South Manchester, UK

*Breast Cancer Research* 2010, **12**(Suppl 3):P32 (doi: 10.1186/bcr2685)

**Introduction** Studies have shown that the combination of MRI and mammography is the most effective screening method for women at high risk of carcinoma, resulting in a recommendation from the National Institute for Health and Clinical Excellence (NICE) for annual surveillance MRI. The purpose of this study is to determine the effectiveness of screening MRI in this group.

**Methods** A retrospective review was performed of all the patients from our family history clinic who were referred for breast MRI screening in accordance with the NICE guidelines. The study period was from July 2008 to July 2010. The recall rate, biopsy rate and outcome were recorded and analysed.

**Results** A total of 233 scans were performed in 173 patients over the 2-year period. Of these, 38 (16.3%) were recalled for a second-look ultrasound scan (US). Fourteen of these underwent biopsy (6%). US-guided core biopsy in 12 patients confirmed six cases of invasive ductal carcinoma and six cases of benign pathology. Two cases were referred for MR-guided biopsy, where one case was shown to be DCIS and the other was shown to be fibrocystic change. Overall, there were seven cases (3% of scans or 4% of patients) of malignancy that were all mammographically occult. Nine of the cases (3.9%) had early repeat MRI scans that were unremarkable. Recall for assessment and cancer detection rates were comparable with published data.

**Conclusions** This study has shown that MRI is an effective screening tool in the surveillance of women at high risk of breast carcinoma.

#### P33

##### Current clinical use of the [<sup>18</sup>F]FDG PET/CT in breast cancer patients: an audit of local referral patterns

NJ Laurence, J Searle, J Bristol, ID Lyburn

Cheltenham General Hospital, Cheltenham, UK

*Breast Cancer Research* 2010, **12**(Suppl 3):P33 (doi: 10.1186/bcr2686)

**Introduction** [<sup>18</sup>F]FDG PET/CT scanning has been shown to be an established, accurate method of detecting many primary and metastatic tumours. However, widespread use of PET/CT scanning in the UK remains generally limited, as it is expensive and restricted to a few tertiary centres. Cheltenham General Hospital receives referrals for patients from across the southwest of England and Wales for [<sup>18</sup>F]FDG PET/CT. We looked at the referral patterns of patients with breast cancer to see whether they reflected current indications for [<sup>18</sup>F]FDG PET/CT and to see whether the findings impacted on clinical decision-making.

**Methods** Ninety-five [<sup>18</sup>F]FDG PET/CT scans from 2006 to 2010 were requested for breast cancer patients. The indications and results of these were recorded and analysed.

**Results** The following indications were found – staging scans in patients with locoregional disease: 22%; equivocal radiology: 17%; specific concern of recurrent disease: 17%; diagnostic/therapeutic conflict with second primary: 15%; staging of locally advanced disease: 11%; response to endocrine or chemotherapy: 9%; stability/speed of progression of metastatic disease: 8%. On reviewing clinical records/follow-up, the results of [<sup>18</sup>F]FDG PET/CT in many circumstances gave information about metastatic disease in locoregional recurrence, resolved issues surrounding equivocal radiology and ensured that patients with second operable cancers were not subjected to major surgery only to succumb to their breast metastasis.

**Conclusions** [<sup>18</sup>F]FDG PET/CT can give valuable information in patients with breast cancer, particularly in scenarios with equivocal findings on other imaging and regarding disease progression. The technique often contributed to management decisions in complex cases.

### P34

#### Incident cancer cases: what can we learn from the previous screening round?

JM Scarth, G Markham, S Kulaveerasingam  
North London Breast Screening Unit, London, UK  
*Breast Cancer Research* 2010, **12**(Suppl 3):P34 (doi: 10.1186/bcr2687)

**Methods** A retrospective analysis of all incident cancers with their previous screening round mammograms diagnosed between April 2006 and March 2008 at the North London Breast Screening unit was performed.

**Results** Two hundred and forty cancers were reviewed. In 187 cases (77.9%) the previous round mammograms were normal (group A), in 53 cases (22.1%) an abnormality was detected (group B). Of these, five (9.4%) were classified as normal/benign, 40 (75.5%) were uncertain and eight (15.1%) were suspicious. There was no significant difference in the size of the lesions between the two groups; there was, however, a significant increase in size in the lesions in group B on the subsequent mammograms ( $P < 0.0001$ ). Of the lesions in group B, 25 (47%) of the cases had microcalcifications only on the previous mammograms; this is higher than previously published data of 27% and 17% [1,2] with all of these cases being subsequently diagnosed as either DCIS or IDC. Group A had less non-invasive (53, 29%) and grade 3 tumours (26, 20%) compared with group B (non-invasive = 18, 34%; grade 3 = 9, 29%) and more grade 1 tumours (51, 39% vs. 8, 26%) with a similar amount of grade 2 tumours between the groups (41% and 45%).

**Conclusions** In 22% of incident cancer cases an abnormality is present on the previous screening round mammogram, and the most frequently overlooked lesions are microcalcifications.

#### References

1. Maxwell AJ, et al.: *Breast* 2001, **10**:392-398.
2. O'Flynn EAM, et al.: *Breast Cancer Res* 2009, **11**(Suppl 2):P8.

### P35

#### Vacuum-assisted core biopsy of B3 lesions showing atypia on needle core biopsy: a worthwhile exercise?

M Al-Attar, S Tennant, E Denton, H Khan, L Grosvenor, D Lister  
University Hospitals of Leicester, UK  
*Breast Cancer Research* 2010, **12**(Suppl 3):P35 (doi: 10.1186/bcr2688)

**Introduction** There has been increasing interest in the use of vacuum-assisted core biopsy (VACB) over the past two decades. There remains some uncertainty about its role in the presence of cytological or architectural atypia on needle core biopsy (NCB). We have recently been offering VACB for selected B3 cases with atypia. MDT discussion, where technical suitability and potential value of VACB is debated, is used to select appropriate cases.

**Methods** A retrospective case review of all B3 lesions diagnosed at NCB between 1 March 2008 and 1 March 2010.

**Results** A total of 166 B3 lesions were diagnosed: 123 underwent surgical biopsy, of which 30 were malignant (eight invasive, 22 non invasive), 10 had LCIS and 83 were benign. Forty-three B3 lesions underwent VACB: 18/43 lesions had shown atypia at NCB and following VACB, seven were upgraded to DCIS, three were downgraded to B2, six remained as B3 with atypia (5/6 had surgery – three malignant, two benign). VACB failed in two cases. Twenty-five out of 43 cases had shown no atypia at NCB. One out of 25 was upgraded to B4 on VACB, but no malignancy was seen at surgery. Twenty-four out of 25 cases were downgraded to B2.

**Conclusions** Our results show a potential benefit of this technique in selected cases. We were able to upgrade 39% of B3 lesions with atypia, thereby allowing immediate definitive surgery. We were able to avoid surgical excision in 3/18 (17%) of B3 lesions with atypia.

### P36

#### Educational abstract

Educational abstract not submitted for online publication.  
*Breast Cancer Research* 2010, **12**(Suppl 3):P36 (doi: 10.1186/bcr2689)

### P37

#### Role of imaging in gynaecomastia: results of a Royal College of Radiologists Breast Group Annual Scientific Meeting 2009 survey

A Leaver, A Yeung, A Redman  
Queen Elizabeth Hospital Breast Screening Unit, Gateshead, UK  
*Breast Cancer Research* 2010, **12**(Suppl 3):P37 (doi: 10.1186/bcr2690)

**Introduction** Gynaecomastia is a benign enlargement of male breast tissue that has no proven excess risk of breast cancer. Clinical evaluation is required to exclude breast cancer, but the role of imaging in the male breast is unclear. Our aim was to determine practice in other units, review literature and formulate informed and realistic departmental guidelines.

**Methods** A questionnaire was created, and copies placed on delegates' seats. Descriptive statistics applied.

**Results** Of approximately 160 delegates, 90 questionnaires were returned from at least 58 different units. Delegates reported (estimated) greater than 864.75 years collective experience, each performing (on average) 4.3 male breast assessments per month. Sixty-five per cent (58/89) of delegates that responded reported routine imaging in clinically typical gynaecomastia, rising to 89% (79/89) in clinically typical unilateral gynaecomastia. However, 78% (68/87) of responding delegates agreed with the statement 'Imaging is not necessary in cases of clinically typical gynaecomastia'. Three delegates reported experiencing a case of ultrasonically typical gynaecomastia that subsequently proved to be breast cancer. Imaging protocol and biopsy practice varied greatly between units. Delegates volunteered concerns that the NHS breast service is inequitable between males and females, and that guidelines were needed to rationalise imaging.

**Conclusions** Based upon questionnaire findings and literature review, guidelines have been now been drawn up in our unit. There is great variation evident in UK gynaecomastia imaging practice. National discussion and agreement on evidence-based guidelines could help rationalize use of precious NHS resources and reduce imaging of this benign condition.

### P38

#### Malignant microcalcification: prediction of excision margins by separating calcified and noncalcified core biopsies

H Cain, A Mooney, J Westgarth, T Fasih, D Browell, K Clark, D Hemming, L Lunt  
Queen Elizabeth Hospital, Gateshead, UK  
*Breast Cancer Research* 2010, **12**(Suppl 3):P38 (doi: 10.1186/bcr2691)

**Introduction** Suspicious microcalcification is investigated by vacuum-assisted core biopsy. Many patients, in whom malignancy is diagnosed, go on to have breast-conserving surgery where positive resection margins require re-operation. The aim of this study was to determine whether there is an increased risk of positive margins when malignancy is identified in cores without microcalcification.

**Methods** In this institute, core biopsy samples are separated into those containing calcification and those not. Sixty-eight consecutive patients undergoing breast-conserving surgery were selected. From the histology report, the presence of malignancy in each group of cores was recorded. The adequacy of margins following the local excision and the need for re-operation was then analysed.

**Results** Sixty-eight patients were included in the study. The mean age at diagnosis was 56.7 (range 40 to 77). All 68 patients had malignancy in the cores containing calcification. Twenty-three (34%) patients had malignancy in these cores alone and nine (39%) of these patients required further surgery. Forty-five patients had malignancy in both of the sets of cores, 24 (53%) required further surgery for inadequate margins. Although there is a difference between the re-operation rate, this is not statistically significant ( $P = 0.3124$ , Fisher's exact test).

**Conclusions** Malignancy is commonly diagnosed in cores that do not contain microcalcification. Although there appears to be a higher rate of inadequate margins in this group (53% vs. 39%), in this study the difference was not statistically significant. Following the findings of this initial study, we are now increasing the sample size of the group.

**P39**

**Initial experience with MicroPure™, a new ultrasound image processing function to improve calcification visualisation**

P Sankaye, G Porter, S Doyle, S Steel

Primrose Breast Unit, Derriford Hospital, Plymouth, UK

*Breast Cancer Research* 2010, **12**(Suppl 3):P39 (doi: 10.1186/bcr2692)

**Introduction** Mammographic calcification may be the only sign of breast malignancy often requiring diagnostic biopsy. If visible, this calcification may be biopsied using ultrasound guidance or using X-ray guidance if not. Ultrasound biopsy is quicker, cheaper and more comfortable for the patient. Any technique that improves ultrasound calcification visualisation is desirable. MicroPure™ (Toshiba Medical Systems Corporation, Otawara, Japan) is a new ultrasound processing technology designed to achieve this.

**Methods** We prospectively audited our experience of calcification detection with B-mode ultrasound and MicroPure™ between April and July 2010. Twenty-five women presenting with a dominant mammographic abnormality of calcification were studied. Targeted imaging with both techniques was performed with a Toshiba Aplio™ XG ultrasound machine using a 12 MHz linear probe. Technical support to optimise imaging was provided during our audit by Toshiba. We recorded ultrasound visibility with these two techniques and histological diagnosis.

**Results** Of 24 screening and one symptomatic woman examined, 11 (44%) were diagnosed with breast malignancy (six invasive cancers, four DCIS, one LCIS), and 14 (56%) were benign. Overall four (16%) (three malignant and one benign) calcifications were visualised by ultrasound. All were detectable using both B-mode and MicroPure™. Subjectively all four were felt to be more conspicuous using B-mode than MicroPure™.

**Conclusions** Our initial experience has demonstrated MicroPure™ to be no better at detecting benign or malignant mammographic calcification than B-mode ultrasound. MicroPure™ would only be useful if it detects calcifications that are not visualised with B-mode ultrasound therefore reducing X-ray-guided biopsies.

**P40**

**A retrospective review of triple-negative breast cancer cases: are there common features in the clinical presentation, imaging and risk factors?**

N Trevett<sup>1</sup>, L Edwards<sup>2,3</sup>, K Gower-Thomas<sup>3,4</sup>, V Shah<sup>2,3</sup>

<sup>1</sup>Welsh School of Medicine, Cardiff, UK; <sup>2</sup>Royal Gwent Hospital, Newport, UK; <sup>3</sup>Breast Test Wales, Cardiff, UK; <sup>4</sup>Royal Glamorgan Hospital, Llantrisant, UK

*Breast Cancer Research* 2010, **12**(Suppl 3):P40 (doi: 10.1186/bcr2693)

**Introduction** Triple-negative breast cancer (TNBC) cases comprise approximately 15% of newly diagnosed breast cancers and are associated with poor prognosis and limited treatment options. In this retrospective study from South Wales, 81 patients with breast cancer found to be ER, PR and HER2 negative were reviewed to determine whether there are common imaging and pathological findings.

**Methods** Patients identified from pathological databases at two hospitals included symptomatic and screening cases. Clinical records were reviewed to determine age at diagnosis, family history and clinical findings; pathological reports to identify size, grade, type and nodal status; and imaging studies to determine breast density, lesion type, classification and size.

**Results** Eighty per cent of patients were aged over 50 years (range 50 to 89 years). Nineteen per cent reported a family history. Eighty-nine per cent were grade 3 tumours, 89% were ductal type of which 30% had associated DCIS. The majority were large tumours (78% over 20 mm). Fifty-two per cent were node positive (20% had more than four nodes positive). Thirty-nine per cent had associated vascular invasion. Calcification was a dominant mammographic feature (37%), 28% had well-defined masses.

**Conclusions** Previous studies have found well-defined masses to be a dominant imaging feature but this study has found malignant calcification to be more common. The tumours were mainly large and frequently associated with vascular invasion, possibly contributing to the poor prognosis despite being node negative in nearly one-half of the cases. There appears to be an association with family history and to be common in the over 50s, contrary to current thinking. A national prospectively collected database TNBC could aid understanding of this group.

**P41**

**Is digital better?**

AA Duncan<sup>1</sup>, ME Wheaton<sup>1</sup>, N Rogers<sup>2</sup>, O Kearins<sup>2</sup>

<sup>1</sup>Warwickshire, Solihull and Coventry Breast Screening Unit, Coventry, UK; <sup>2</sup>West Midlands QA Reference Centre, Birmingham, UK

*Breast Cancer Research* 2010, **12**(Suppl 3):P41 (doi: 10.1186/bcr2694)

**Introduction** During the changeover from analogue to digital screening in the UK, reassurance is needed to confirm that the outcomes with digital are equal to or better than analogue screening.

**Methods** Warwickshire, Solihull & Coventry Breast Screening Service commenced the phased conversion to digital screening in 2005, with a single digital machine on one of three mobiles. This retrospective study compares the screening outcomes of 138,173 women aged between 49 and 70 years screened on analogue or digital imaging between April 2005 and March 2009 inclusive. Approximately one-third of these were screened using digital, the remainder on analogue.

**Results** The results show no difference in the rates of screen-detected cancer in prevalent or incident groups between analogue and digital, and rates were stable with time. Similar proportions of invasive and non-invasive cancers were detected in both groups and tumour size was not significantly different. No significant increase in cancer detection in younger compared with older women was seen in the digital group, and digital did not diagnose a higher proportion of lobular cancers. No difference in interval cancer rates between the two methods of screening was seen. On radiological subclassification of interval cancers into normal/benign, uncertain and suspicious, significantly fewer interval cancers were classified as uncertain in the digital than the analogue screening group. See Table 1.

**Table 1 (abstract P41)**

	Analogue		Digital	
	n	% (95% CI)	n	% (95% CI)
Normal/benign	97	73.5% (66.0 to 81.0%)	72	85.7% (7.02 to 93.2%)
Uncertain	20	15.2% (9.0 to 21.3%)	3	3.6% (-0.4 to 7.5%)
Suspicious	15	11.4% (5.9 to 16.8%)	9	10.7% (4.1 to 17.3%)

**Conclusions** These results are reassuring that digital diagnoses similar cancers to analogue screening, and suggest that digital may allow more definitive interval cancer classification.

**P42**

**Variability in film reader estimates of breast density in the PERFORMS scheme**

IT Darker, AG Gale, Y Chen

Loughborough University, Loughborough, UK

*Breast Cancer Research* 2010, **12**(Suppl 3):P42 (doi: 10.1186/bcr2695)

**Introduction** All UK screening personnel are invited to take part annually in the PERFORMS self-assessment scheme where they make several judgements about series of challenging recent screening cases. As part of this process they assess the density of each case. Density is a factor known to be associated with a greater risk of developing breast cancer and thus accurate density judgements may well presage the facility to proffer improved follow-up for individual women. The present study examines the degree of variability amongst film reader estimates of breast density on a large number of cases.

**Methods** Data were examined from the most recent 2 years of the PERFORMS scheme where breast density estimates were made for each case examined using a three-point rating scale of fatty, mixed density, and dense. These data comprised information from 444 individuals (mainly consultant radiologists, advanced practitioners and breast physicians) who had all examined the same 240 difficult cases.

**Results** The inter-rater reliability, corrected for chance agreements, was assessed using kappa. Overall, the degree of agreement across cases on breast density category was significantly greater than no agreement ( $P < 0.0001$ ). However, only a moderate degree of inter-rater reliability was

exhibited,  $\kappa = 0.470$ . There were significant differences between the levels of agreement amongst the ratings of the radiologists, advanced practitioners and others (all  $P < 0.05$ ).

**Conclusions** The low agreement rates between participants for density ratings were surprising. That there were differences between the occupational groupings may reflect breast screening experience.

#### P43

##### Seeding of tumour cells following breast biopsy: a literature review

CF Loughran, C Keeling

Macclesfield District General Hospital, Macclesfield, UK

Breast Cancer Research 2010, 12(Suppl 3):P43 (doi: 10.1186/bcr2696)

**Introduction** This literature review examines evidence relating to needle biopsy of the breast and the potential for later tumour cell migration into adjacent tissues.

**Methods** A literature search was undertaken, using Medline, Embase and the Cochrane Library.

**Results** The results were analysed by the following: (1) Histological evidence of spread (seven papers addressing this were scrutinised; number of patients reviewed was 1,046). Tumour cell displacement occurs in about one-third of patients, the majority do not survive displacement. Vacuum biopsy techniques may reduce seeding potential. (2) Clinical evidence of recurrent disease (nine papers were scrutinised; number of patients reviewed was 1,575). Sporadic reports of tumour recurrence suspected to be a consequence of a biopsy procedure are described. Care to excise the site of needle biopsy is advised by some, especially if outside the radiotherapy field. (3) Likelihood of seeding dependent upon tumour type (three papers were scrutinised; number of patients reviewed was 258). There is limited evidence to suggest lobular carcinoma is less likely to seed than ductal.

**Conclusions** There is histological evidence of seeding of tumour cells from the primary neoplastic site into adjacent breast tissue, following biopsy. However, clinical recurrence at the site of a needle biopsy is uncommon. This event may be lessened by use of vacuum biopsy techniques. The site of needle biopsy should be considered at the time of surgery.

#### P44

##### How can the prevalent round recall rate be reduced?

A Ramakrishnan, I Haigh, J Liston, BJG Dall, N Sharma

Leeds Teaching Hospital NHS Trust, Leeds, UK

Breast Cancer Research 2010, 12(Suppl 3):P44 (doi: 10.1186/bcr2697)

**Introduction** The prevalent round recall rate is higher than the incident recall rate. Implementation of age extension will lead to two prevalent rounds and with this increased clinical and financial pressure on screening units. Any processes that help reduce the recall rate will be of benefit to screening units.

**Methods** Retrospective data were collected from April 2008 to March 2009 of prevalent round ladies recalled to assessment clinics. The data recorded included reason for recall, imaging findings and needle test results.

**Results** A total of 7,627 women were invited for screening in April 2008 to March 2009, of which 5,341 attended. Four hundred and eighty-one ladies were recalled to assessment; 451/481 of the packets available were reviewed. Forty cancers were identified in 39 patients. All cases of malignancy were coded as RU, RS or RM at the time of film reading. Thirty-two patients were recalled for both sides, four patients recalled for two lesions within the same breast. Nineteen patients were clinical recalls (BA). All solitary RB masses thought to be benign at the time of film reading proved to be benign (91/215 masses). Ten cases recalled for bilateral RB masses were benign. Thirty-six out of 140 asymmetries thought to be benign at the time of film reading were benign.

**Conclusions** The recall rate may be reduced in the prevalent round by not recalling solitary RB masses, bilateral RB masses, and asymmetry that appears physiological/benign on two views. In this unit this would have reduced the recall rate without adversely affecting the cancer detection rate.

#### P45

##### Educational abstract

Educational abstract not submitted for online publication.

Breast Cancer Research 2010, 12(Suppl 3):P45 (doi: 10.1186/bcr2698)

#### P46

##### Breast histoscanning: the development of a novel technique to improve tissue characterization during breast ultrasound

LS Wilkinson, C Coleman, CM Pagliari, P Skippage, V Thomas, R Given-Wilson

St George's Healthcare NHS Trust, London, UK

Breast Cancer Research 2010, 12(Suppl 3):P46 (doi: 10.1186/bcr2699)

**Introduction** Imaging alone cannot reliably distinguish benign/malignant breast disease or assess the extent of cancer. This study assesses the feasibility of using additional information obtained at US (BHS) to aid diagnosis and preoperative assessment.

**Methods** 3D US scans at 8 MHz, 12 MHz, 15 MHz were obtained of breast tissue in normal volunteers in two planes and with/without harmonics. Five volumes of sagittal scans at 8 MHz from three individuals were used to identify normal characteristics and define the baseline. The 3D volume was divided into voxels (0.1 x 2 x 1.5 mm) and raw data from each voxel were analysed by applying linear and nonlinear classifiers to assess 29 statistical characteristics (BHS). The training dataset contained 300,000 voxels. After training, the classifier's output showed 3% error on both normal and abnormal tissue. The algorithm was tested on 32 further volumes representing 6,000,000 voxels of normal and abnormal tissue from 20 individuals. Abnormal tissue included various biopsy-proven lesions: malignancy (six), papilloma (one), hamartoma (one), fibroadenoma (two), cyst (two), fibrosis (one). Subclassifiers were developed to distinguish between cancer and benign voxels.

**Results** In 17 normal testing volumes, 3% of isolated voxels were classified as abnormal. In 15 abnormal testing volumes, the subclassifiers differentiated between malignant and benign tissue. BHS in benign tissue showed <1% abnormal voxels in cyst, hamartoma, papilloma and benign fibrosis. The fibroadenomas differed showing <5% and <24% abnormal voxels. Abnormal voxels in cancers increased with the volume of cancer at pathology.

**Conclusions** Histoscanning reliably discriminated normal from abnormal tissue and could distinguish between benign and malignant lesions.

#### P47

##### Single voxel proton magnetic resonance spectroscopy of breast cancer at 3T

JKP Begley<sup>1</sup>, TW Redpath<sup>2</sup>, B Jagpal<sup>2</sup>, FJ Gilbert<sup>2</sup>

<sup>1</sup>University of Aberdeen, UK; <sup>2</sup>Aberdeen Biomedical Imaging Centre, University of Aberdeen, UK

Breast Cancer Research 2010, 12(Suppl 3):P47 (doi: 10.1186/bcr2700)

**Introduction** *In vivo* detectability of a signal (tCho) from choline containing molecules at ~3.2 ppm by MR spectroscopy (MRS) can be useful as a biomarker for malignancy. tCho has also been observed in benign, normal, and lactating breast, therefore quantitation is vital. The aim is to assess whether tCho detectability can differentiate between benign and malignant breast disease and to implement internal water-referenced choline quantitation at 3T.

**Methods** Women with histologically confirmed breast cancer or suspicious features were identified either at MDT or following referral for clinical breast MRI and recruited following informed consent. Studies were performed on 3T Philips Achieva (the Netherlands). Contrast-enhanced MRI localised the region for point-resolved spectroscopy (PRESS) evaluation. Spectral processing was performed with jMRUI. The choline concentration was determined using the unsuppressed intravoxel water resonance as a reference. tCho detectability and choline concentration were correlated with known pathological information. Results were analysed by JKPB.

**Results** Nine participants (age range, 38 to 73 years) were successfully examined. tCho was detected at ~3.2 ppm in four of nine lesions (lesion size, 0.8 to 7.0 cm; mean, 3.0 cm), providing a sensitivity and specificity of 67% and 100%, respectively. The two quantitative values of 2.13 and 5.59 mmol/kg are consistent with previously reported findings.

**Conclusions** MRS is a non-invasive and non-ionising means of analysing lesion metabolism as an adjunct to clinical MRI. Whilst potentially useful for differentiating between benign and malignant breast diseases, implementation is challenging. Using clinical 3T systems, internal water referencing can successfully quantify choline in patients with breast cancer.

**P48**

**Benefits of CT-angiography localisation in the surgical planning of deep inferior epigastric perforator flap breast reconstruction**

NC Chhaya<sup>1</sup>, P Sarbeng<sup>1</sup>, S Stuart<sup>1</sup>, F Angullia<sup>2</sup>, A Mosahebi<sup>2</sup>, A Malhotra<sup>1</sup>

<sup>1</sup>Department of Radiology, Royal Free Hospital, London, UK; <sup>2</sup>Department of Plastic Surgery, Royal Free Hospital, London, UK

*Breast Cancer Research* 2010, **12**(Suppl 3):P48 (doi: 10.1186/bcr2701)

**Introduction** The aim of breast reconstruction in the postmastectomy cancer patient is to restore breast contour and dimensions whilst minimising the cosmetic impact. The deep inferior epigastric perforator (DIEP)-flap is a complex but state-of-the-art procedure that provides a durable and natural result. It is rapidly becoming the preferred choice at many institutions, including our regional plastic surgery unit. In achieving superior cosmesis without sacrificing abdominal wall musculature, a successful DIEP-flap requires painstaking and time-consuming microdissection of the inferior epigastric artery perforators. This relies on a high level of surgical expertise and results in prolonged anaesthetic times. As greater volumes of breast reconstructive surgery are performed, there will be increasing requirements for such preoperative imaging. We describe the required optimisation of CTA protocols to obtain the pertinent information and demonstrate how best to convey this complex information to our surgical colleagues.

**Methods** Since 2009 we have provided CT-angiography in the preoperative planning for DIEP-flap breast reconstruction. We explored the implications of CT-angiography to optimise localisation of arterial perforators and identified the benefits of this imaging-guided approach.

**Results** A total of 60 female patients have benefitted from CTA-guided perforator localisation, providing valuable procedural-planning information to our surgical colleagues. We have shown benefits in terms of markedly shorter operative duration with consequently reduced hospital stays and morbidity. Two patients had unsuspected metastatic disease identified, precluding reconstructive surgery.

**Conclusions** An imaging-guided approach optimises preoperative planning. Accurate identification of arterial perforators enables targeted intraoperative localisation. This results in decreased operative time and patient morbidity, providing benefits for the cost of healthcare provision.

**P49**

**Interval breast cancers: positive influencing behaviour**

A Kumar, G Penn, D Meacock, H Yeang

Wirral University Teaching Hospital, Liverpool, UK

*Breast Cancer Research* 2010, **12**(Suppl 3):P49 (doi: 10.1186/bcr2702)

**Introduction** Studies estimate that 10 to 32% of breast cancers are overlooked in mammograms. One of the important causes of interval breast cancer is fatigue and loss of concentration. The likelihood of fatigue increases with the duration of a reporting session and errors are more likely to occur towards the end of the session. The purpose of this talk is to address the lack of awareness of the issues that drive reporting performance.

**Methods** A retrospective study was carried out on interval breast cancers from a 2-year period. This identified 90 histopathologically proven interval breast cancers. Each interval cancer mammogram was reviewed by two blinded consultant radiologists and placed into one of three categories on retrospective radiological review: Category 1: normal; Category 2: uncertain; Category 3: suspicious. Each case was then analysed further to correlate the interval categories with their position on the mammography roller viewer.

**Results** Of the 90 interval breast cancers, 59 (66%) were Category 1, 14 (16%) were Category 2 and 17 (18%) were Category 3. Statistical analyses with one-way ANOVA test revealed the presence of clinical significance between Category 3 cases and their position in the roller viewer ( $P < 0.021$ ).

**Conclusions** Fatigue is identified as an important factor responsible for missing breast cancer. Aside from making changes in double-reporting techniques, human performance factors such as nutrition, rest, behaviour prior to reporting and environment have to be considered. A national programme has to be implemented to facilitate a plan to raise awareness of these factors in the NHS culture.

**P50**

**Educational abstract**

Educational abstract not submitted for online publication.

*Breast Cancer Research* 2010, **12**(Suppl 3):P50 (doi: 10.1186/bcr2703)

**P51**

**Educational abstract**

Educational abstract not submitted for online publication.

*Breast Cancer Research* 2010, **12**(Suppl 3):P51 (doi: 10.1186/bcr2704)

**P52**

**Benign solitary breast masses in the prevalent screening round: do they contribute to a high recall rate?**

N Hoskins<sup>1</sup>, L Edwards<sup>2</sup>, K Gower-Thomas<sup>2</sup>, V Shah<sup>2</sup>

<sup>1</sup>Welsh School of Medicine, Cardiff, UK; <sup>2</sup>Breast Test Wales, Cardiff, UK

*Breast Cancer Research* 2010, **12**(Suppl 3):P52 (doi: 10.1186/bcr2705)

**Background** The Breast Test Wales prevalent round recall rate between 2003 and 2006 was 9.07% (above the NHSBSP target of 7%) and remains high. This study was based on the hypothesis that recall of benign solitary masses might be a major contributor to this as no prior imaging is available.

**Methods** Prospectively collected data from Breast Test Wales (South East Wales) identified all prevalent screens in a 3-year cycle recalled for a benign mass lesion confirmed by core biopsy. All women attended a subsequent screen and remained free of cancer. Mammograms were retrospectively reviewed and the lesions were re-evaluated by applying criteria typical of a benign mass.

**Results** A total of 2,322 women following a prevalent screen were recalled; 2,069 were returned to routine recall without biopsy (cysts are included in this group), 186 were diagnosed with cancer and 105 had a benign biopsy where mammography had been considered benign or probably benign. The benign to malignant biopsy ratio was 1:1.8. A total 46.6% ( $n = 49$ ) lesions on retrospective review of mammography showed typical benign characteristics. Dense breast composition and overlying glandular tissue were noted to correlate with higher rates of retrospectively indicated recall.

**Conclusions** Stricter adherence to applying classification of benign solitary lesions could reduce the recall rate and decrease the psychological distress for these women without adversely compromising the cancer detection rate. The impact on the overall recall rate would be small but would significantly improve the benign to malignant biopsy ratio. The issue of breast density and overlying tissue may be resolved with the advent of digital applications such as tomosynthesis.

**P53**

**Breast MRI screening for high-risk family history: the Sheffield experience**

AV Genever, E Surgey, AL Ford, O Hatsiopoulou, CE Ingram, IJ Jolley

Breast Unit, Sheffield Teaching Hospitals NHS Trust, Sheffield, UK

*Breast Cancer Research* 2010, **12**(Suppl 3):P53 (doi: 10.1186/bcr2706)

**Introduction** Around 5% of breast cancers can be attributed to gene mutations. NICE guidelines have recently advocated the use of MRI screening in high-risk young women. We have retrospectively audited our unit's experience in this field.

**Methods** All eligible women were identified from the family history database. Notes, imaging and pathology were reviewed.

**Results** One hundred and thirty-three breast MRI scans were performed on 91 women with a high-risk family history between 2007 and 2010. Sixteen women were recalled for assessment (one woman was recalled twice). The total recall rate was 12.7%. Of the recalled patients, four had normal ultrasound (US) and follow-up imaging has remained unchanged. Thirteen patients had corresponding US-detected abnormalities. Twelve were biopsied, the other was a normal intramammary lymph node. Eight of the biopsies were benign (benign core biopsy rate 6%). Four biopsies were malignant (age range of women 35 to 45), giving a cancer detection rate of 3%. Three of these were solitary lesions (8 mm, 11 mm and 16 mm). One patient had multifocal malignancy, the largest single lesion being 16 mm. All were node-negative ductal carcinoma. Two patients were oestrogen receptor-positive, all were herceptin receptor-negative. Only the extensive malignant change could be seen on conventional mammography.

**Conclusions** We suggest that MRI screening is beneficial in these patients, and although our recall rate lies a little above what is to be recommended by the NHSBSP (7 to 10%) we feel this can be attributed to the steep learning curve that introducing a new screening technique to a service invariably brings.

**P54**

**Educational abstract**

Educational abstract not submitted for online publication.  
*Breast Cancer Research* 2010, **12**(Suppl 3):P54 (doi: 10.1186/bcr2707)

**P55**

**Correlation of preoperative ultrasound and mammographic measurement of malignant breast masses with operative histology**

M Mansi<sup>1</sup>, A Leaver<sup>2</sup>, L McLean<sup>2</sup>, B Kaye<sup>2</sup>  
<sup>1</sup>School of Medicine, University of Newcastle upon Tyne, UK; <sup>2</sup>Royal Victoria Infirmary, Newcastle upon Tyne, UK  
*Breast Cancer Research* 2010, **12**(Suppl 3):P55 (doi: 10.1186/bcr2708)

**Introduction** Preoperative assessment of breast cancer patients is by physical examination, mammography and ultrasound. Mammography and ultrasound measurements inform treatment regimes and prognostic estimates. Our aim was to determine the accuracy of imaging measurement of malignant breast masses in our Trust.

**Methods** Screening and symptomatic women with breast cancer who had surgery between October 2008 and May 2009 were identified from multidisciplinary team records. The largest dimension of abnormal tissue/breast mass on any projection/probe orientation was documented for mammography and/or ultrasound. Measurements were compared with the largest tumour dimension on final histological analysis of excised tumour.

**Results** Records were available for 100 patients with invasive breast cancer (66% (66/100) invasive without DCIS, 34% (34/100) invasive with DCIS). Overall size of the malignancy measured at both mammography and ultrasound correlated with histological tumour size ( $r = 0.54$  and  $r = 0.56$ , respectively). This correlation was less high for overall size of malignancy when associated with DCIS. Mammography with DCIS ( $r = 0.37$ ) versus mammography without DCIS ( $r = 0.77$ ); ultrasound with DCIS ( $r = 0.52$ ) versus  $r = 0.68$  for invasive cancers without DCIS. Multiple regression analysis showed that the combination of mammogram and ultrasound is an effective means of estimating size of malignancy in the presence of a mass ( $r^2 = 0.67$ ).

**Conclusions** The combination of mammography and ultrasound is an effective means of predicting tumour size; it is more accurate for tumours without DCIS. There is a tendency towards size underestimation, more so for ultrasound than mammography.

**P56**

**Educational abstract**

Educational abstract not submitted for online publication.  
*Breast Cancer Research* 2010, **12**(Suppl 3):P56 (doi: 10.1186/bcr2709)

**P57**

**What is involved in a comprehensive breast MRI service? Implications for service provision**

ND Forester, N Sharma, BJG Dall  
Leeds Teaching Hospitals Trust, Leeds, UK  
*Breast Cancer Research* 2010, **12**(Suppl 3):P57 (doi: 10.1186/bcr2710)

**Introduction** MRI as an adjunct to triple assessment is well established, but often identifies additional lesions within the breast necessitating further characterisation. This study addresses the additional investigations generated by MRI.

**Methods** A retrospective review of the MRI database between 2006 and 2009 identifying patients requiring investigations post MRI.

**Results** Over 4 years, 1,119 MRIs were performed on 717 patients, with 102 recalled for second-look ultrasound. Three patients were lost to follow-up. A total 124 incidental lesions were identified on MRI. Ultrasound identified 68 lesions, with definitive diagnosis following core biopsy/FNAC (62), surgery (two) core biopsy + repeat MRI (one) and MRI biopsy (three). Twenty-two lesions not identified by USS were assessed with X-ray-guided biopsy (two), MRI biopsy (13), interval MRI (five) or surgery (two). Nineteen MRI lesions following normal ultrasound had routine follow-up. Fifteen lesions (12 patients) did not have follow-up USS, as recommended following MDT discussion. Sixty lesions (44 patients) were malignant; MRI identified a primary in four patients presenting with lymphadenopathy and in 39 patients identified additional foci that changed management. Malignant

lesions were identified on US biopsy/FNAC (38), X-ray-guided biopsy (one), MRI biopsy (seven) and surgery (14).

**Conclusions** MRI identifies additional foci in 14% of patients. Malignant lesions will be identified in 43% of patients recalled. Comparison with 2005 data identifies a decreased recall rate and an increased cancer detection rate. Fifty per cent of additional lesions identified by MRI are malignant, of which 77% were confirmed preoperatively. Provision of a comprehensive breast MRI service must consider the resources needed to deliver the additional diagnostic investigations required.

**P58**

**An audit of pain in ultrasound-guided breast core biopsy**

P Whelehan, L Baker, A Evans  
University of Dundee, UK  
*Breast Cancer Research* 2010, **12**(Suppl 3):P58 (doi: 10.1186/bcr2711)

**Introduction** We audited pain from ultrasound-guided core biopsies (CB) for routine service quality monitoring, to provide baseline data against which to compare new techniques, and to help us develop methodological expertise in pain assessment. Although there is no standard against which to audit CB pain, published comparators are available.

**Methods** Two self-report pain scales were administered to 64 female patients immediately after ultrasound-guided 14G CB under local anaesthesia. Although we aimed for consecutive patients, some were de-selected by staff on grounds of apparently high levels of cancer anxiety. The scales were a 100 mm visual analogue scale (VAS) and a four-category verbal rating scale (VRS) – None, Mild, Moderate, Severe. Responses were anonymous and no attempt was made to collect data on relevant variables. VAS scores were compared between VRS categories using the Mann-Whitney U test.

**Results** Sixty questionnaires were adequate for analysis. VAS scores were not normally distributed and ranged from 0 to 80, median 7.5, interquartile range 15 (mean  $15.6 \pm$  SD 22.3). The paired VAS and VRS results correlated well and the median VAS scores for the different VRS categories demonstrated clear distinctions between categories ( $P < 0.001$ ).

**Conclusions** The correlation between VAS scores and VRS categories is evidence supporting the validity of the scales. Our overall mean VAS score was lower than the most comparable values in the literature. We will use our audit to illustrate a discussion of the principles, including scale selection, and the pitfalls of pain assessment in relation to existing relevant literature.

**P59**

**Educational abstract**

Educational abstract not submitted for online publication.  
*Breast Cancer Research* 2010, **12**(Suppl 3):P59 (doi: 10.1186/bcr2712)

**P60**

**Breast cancer screening in the over 70s**

D Eddy<sup>1</sup>, L Edwards<sup>2</sup>, K Gower-Thomas<sup>2</sup>  
<sup>1</sup>Welsh School of Medicine, Cardiff, UK; <sup>2</sup>Breast Test Wales, Cardiff, UK  
*Breast Cancer Research* 2010, **12**(Suppl 3):P60 (doi: 10.1186/bcr2713)

**Introduction** Routine invitation for breast screening currently ceases in Wales over the age of 70 despite the incidence of breast cancer remaining high in this group. Attendance for screening aged over 70 is low compared with the invited population, often attributed to lack of awareness of eligibility and how to access screening. If screening is to be extended, the motivation to attend and outcomes need to be understood.

**Methods** This audit of prospectively collected data from Breast Test Wales Screening (South East Wales) identified all women over 70 years who attended. In those where cancers were detected, age, pathological data, previous screening history, family history, clinically palpability and breast symptoms were recorded.

**Results** A total of 5,736 women attended aged 71 to 92 years in a 3-year screening round (1 April 2006 to 31 March 2009) with numbers attending decreasing with higher age. In total, 295 (5.1%) were recalled to assessment and 81 (1.4%) were diagnosed with cancer. A total of 61.5% of the cancers were grade 2, 77%  $< 20$  mm and 84% node-negative. The majority had an excellent or good Nottingham Prognostic Index, mirroring national data for the younger invited population. Of those diagnosed with cancer, 61.6% had

four or more previous screens; 28.9% of women reported a family history; 55.4% were clinically palpable and of these 49% had themselves noticed a change in the breast.

**Conclusions** This study indicates that women continue to attend regularly after invitation ceases. Clinical concerns and family history awareness may be motivators but as cancers detected have good prognostic indices, screening this group may be beneficial.

#### P61

##### Are there features on imaging or core biopsy that can predict tumour-positive margins after breast-conserving surgery?

N Hill<sup>1</sup>, L Edwards<sup>2</sup>, IJ Monypenny<sup>2</sup>, K Gower-Thomas<sup>2</sup>

<sup>1</sup>Welsh School of Medicine, Cardiff, UK; <sup>2</sup>Breast Test Wales, Cardiff, UK  
*Breast Cancer Research* 2010, 12(Suppl 3):P61 (doi: 10.1186/bcr2714)

**Introduction** Twenty-two per cent of women required further surgery following breast-conserving surgery (BCS) in the UK in 2008 because of involved margins. This study was carried out to see whether it was possible to predict the likelihood of this from preoperative information and thus reduce the re-excision rate.

**Methods** Women having BCS following a preoperative diagnosis of invasive cancer were identified from prospectively collected data at Breast Test Wales for South East Wales, over a 3-year screening round (2006 to 2009). In cases where DCIS was found at or within 2 mm of a margin, preoperative imaging was reviewed to look for peripheral calcification.

**Results** One hundred and twelve out of 844 women with an invasive tumour had involved margins after BCS. Fifty-nine women had DCIS at the margin, of which 60% had calcification within 10 mm of the periphery of the tumour on mammographic review and 30% had DCIS as well as invasive cancer on core biopsy. The postsurgical pathological size was greater than the mammographic size in 79% and greater than the ultrasound size in over 90% of cases. This was not significantly changed on further review of the films. On mammographic review, 12% had dense breasts, 88% being fatty or fatty/glandular.

**Conclusions** Imaging is underestimating the true size despite background breast tissue being fatty. The presence of calcification on the mammogram in such a high number of cases where DCIS is at the margin may be a useful predictor, but requires further correlation with the presence of histological calcification on the pathological specimen, which is ongoing.

#### P62

##### Educational abstract

Educational abstract not submitted for online publication.

*Breast Cancer Research* 2010, 12(Suppl 3):P62 (doi: 10.1186/bcr2715)

#### P63

##### Ultrasound of the axilla: analysing nodal cortical thickness

PM Riley, S Datta, H Alwan-Walker, S Limdi

Salford Royal Foundation Trust, Manchester, UK

*Breast Cancer Research* 2010, 12(Suppl 3):P63 (doi: 10.1186/bcr2716)

**Introduction** Prognosis in breast cancer is dependent upon axillary lymph node status. For breast-conserving surgery, lymph node status can

be assessed via sentinel lymph node procedures (SLNP) [1]. This can be time consuming, however, and it would be useful to identify a subset of quantitative nodal features on ultrasound in order to predict metastatic involvement and avoid the SLNP. Peer review states that cortical thickness is one of the best predictive characteristics [1,2]. We wanted to interrogate our own data with a specific focus on this feature.

**Methods** A retrospective study of 454 patients audited between August 2007 and October 2009. One hundred and thirty-seven had proven breast cancer and underwent axillary node sampling.

**Results** In 75 cases the cortical thickness was recorded. Comparing with sentinel node biopsy or postoperative pathology, the results are as shown in Figure 1.

**Conclusions** The study confirms that the nodal cortical thickness correlates well with the presence of disease. It is easy to measure and appears to be a reliable indicator. Further, the minimum cortical thickness for positivity (27 mm) will help us to grade our degree of suspicion in future.

##### References

1. Kuenen-Boumeester V, Menke-Pluymers M, de Kanter A, *et al.*: Ultrasound guided fine needle aspiration cytology of axillary lymph nodes in breast cancer patients. A pre-operative staging procedure. *Eur J Cancer* 2003, 39:170-174.
2. Damera A, Evans AJ, Cornford EJ, *et al.*: Diagnosis of axillary nodal metastases by ultrasound guided core biopsy in primary operable breast cancer. *Br J Cancer* 2003, 89:1310-1313.

#### P64

##### Breast cancer in 35 to 39 year olds and imaging: is changing to ultrasound without mammography going to be safe? What are the workload implications?

G Rubin, C Zammit

Brighton and Sussex University Hospitals NHS Trust, Brighton, UK

*Breast Cancer Research* 2010, 12(Suppl 3):P64 (doi: 10.1186/bcr2717)

**Introduction** New guidelines suggest that ultrasound should replace mammography as the primary imaging test for 35 to 39 year olds in symptomatic outpatient clinics. We currently use clinical examination, clinically guided fine needle aspiration and mammograms for women aged 35+ as initial triple assessment. We wanted to understand the implications of introducing the guidelines, based on our current practice.

**Methods** We reviewed our workload and cancer detection in symptomatic 35 to 39 year olds attending breast outpatients in our district general hospital over the past 18 months.

**Results** Mammograms were taken on all symptomatic patients unless pregnant or breastfeeding. Seven hundred and fourteen patients had mammograms and 442 patients had ultrasound. This was performed on most patients found to have clinically palpable lumps, and on anyone with a clinical examination graded as uncertain suspicious or malignant, or with abnormal mammograms, or with abnormal results on clinically guided needle cytology. Fourteen patients were found to have breast cancer. All 14 had ultrasounds graded as uncertain, suspicious or malignant, an indication for diagnostic core biopsy. Thirteen cancer patients had mammograms. Two were graded as benign and 11 as uncertain or worse. Five cancer patients had clinically normal or benign breast examinations, including one with a benign mammogram report.

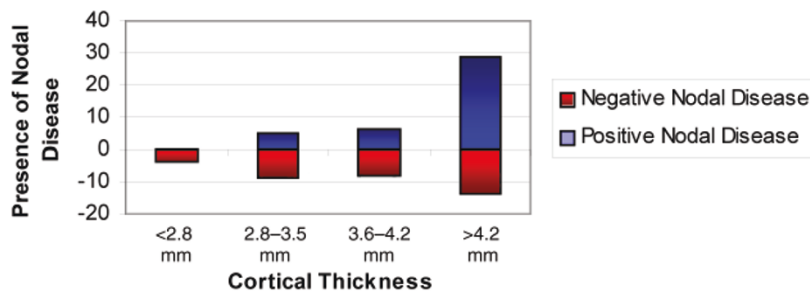


Figure 1 (abstract P63). Cortical thickness in nodal disease.

**Conclusions** Ultrasound missed no cancers but mammograms missed two out of 13. This supports implementing the guidelines. However, this would mean a 38% increase in the number of ultrasounds, 15 extra each month. This extra ultrasound capacity may be hard to provide but will be offset by fewer mammograms.

**Cite abstracts in this supplement using the relevant abstract number, e.g.:** Rubin G, Zammit C: Breast cancer in 35 to 39 year olds and imaging: is changing to ultrasound without mammography going to be safe? What are the workload implications? *Breast Cancer Research* 2010, 12(Suppl 3):P64.